

Clinical Technique/Case Report

Modified Matrix Band Design for Ultra-conservative Posterior Restorations

S Deliperi

Clinical Relevance

The combination of minimally invasive cavity preparations and adhesive restorations allows clinicians a significantly more conservative approach to proximal carious lesions of teeth adjacent to MO/DO preparations.

SUMMARY

Conventional box preparations, tunnel cavities and slot preparations have been recommended for the treatment of proximal carious lesions over the years. If the adjacent tooth is missing or the proximal surface becomes accessible at the time of cavity preparation of the adjacent tooth, a direct proximal access to the decay process can be performed. A similar procedure is supported by the use of adhesive composite restorations reinforcing the remaining sound tooth structure. The increasing patient and clinician's desire for ultraconservative treatment justifies this minimally invasive tooth preparation approach; however, appropriate materials and techniques need to be selected to achieve adequate bonding of the cavity walls and marginal adaptation of the composite.

INTRODUCTION

Since the development of adhesive systems for composite restorations, two restorative models for the treatment of carious lesions have coexisted. The older system is based on Black's principles, which center on resistance of the restoration rather than the tooth;¹ these principles are still adopted for posterior non-adhesive amalgam restorations and lead to unnecessary tooth-structure loss coupled with long-term increased probability of secondary decay.² The second model was introduced more recently and is based on a defect-related approach. The outline form of the cavity depends on the size, location and morphology of the carious process; no undercuts or minimal preparation depths are required. Particular attention is directed to the conservation of sound tooth structure to achieve strength of the tooth/restoration compound and pulp protection, using enamel-dentin adhesive systems.³⁻⁴

The marginal ridge of posterior teeth represents a strategic structure for residual tooth strength maintenance. A minimally invasive dental approach is directed to the retention of these structures through alternative access pathways. If proximal caries exists on the adjacent tooth contiguous to the lesion, a direct access to the

*Simone Deliperi, DDS, adjunct assistant professor, Tufts University School of Dental Medicine, Boston, MA, USA and private practice, Cagliari, Italy

*Reprint request: Via G Baccelli, 10/b, 09126 Cagliari, Italy; e-mail: simone.deliperi@tufts.edu

DOI: 10.2341/07-126

lesion is suitable.² However, the freehand restoration of a similar lesion is very challenging and may be responsible for the formation of composite flash or overhang. This case report presents a modified-matrix band design used to properly restore the cavosurface margins of proximal direct-access lesions.

CASE REPORT

Restorative Procedure

A 21-year old female patient presented with multiple carious lesions on the lower molars and premolars (Figure 1). A rubber dam was placed and the cavity was prepared in a very conservative manner on teeth #20 and #21, just removing decay with #2 and #4 round burs, respectively (Shofu Dental Corporation, San Marcos, CA, USA) and rounding sharp angles with #2 high- and low-speed round burs (Shofu Dental Corporation). Once the caries-affected distal surface of tooth #21 was removed, a decay process on the mesial surface of tooth #20 was also detected. Caries was removed using a #2 round bur in an attempt to preserve the mesial proximal ridge and occlusal surface (Figures 2 and 3). No bevels were placed either in the occlusal or gingival margins. A polyester circular matrix (SuperMat-KerrHawe, Orange, CA, USA) was modified using a dental bur. A hole, with a diameter similar to that of the cavity, was created on one side of the matrix (Figure 4); then, the modified matrix was placed around tooth #20 and tightened to secure gingival matrix adaptation (Figure 5). The cavity was disinfected with a 2% chlorhexidine antibacterial solution (Consepsis-Ultradent Products, South Jordan, UT, USA) and etched for 15 seconds using a 35% phosphoric acid etchant (Scotchbond Etchant, 3M ESPE, St Paul, MN, USA) (Figure 6). The etchant was removed and the cavity rinsed with water spray for 30 seconds, being careful to maintain a moist surface. A fifth-generation nanofilled ethanol-water based adhesive system (Single Bond Plus, 3M ESPE) was placed in the preparation and gently air thinned and light cured for 20 seconds using a Quartz Tungsten Halogen curing light (VIP, BISCO, Inc, Schaumburg, IL, USA) (Figure 7).

Stratification of the dentin was started, placing a 1 to 1.5 mm even layer of flowable composite (Filtek Flow, 3M ESPE) on deeper dentin, which was followed by the application of A3.5 dentin wedge-shaped increments of Filtek Supreme Plus nanofilled resin composite (3M ESPE). An A1 enamel shade was applied to the final contour on the proximal enamel surface (Figure 8).

At this point, sectional matrixes were placed on the remaining proximal surfaces still in need of restoration. Gingival adaptation was secured with wooden wedges (Figure 9). The restoration of teeth #20 and #21 was performed using the same materials adopted

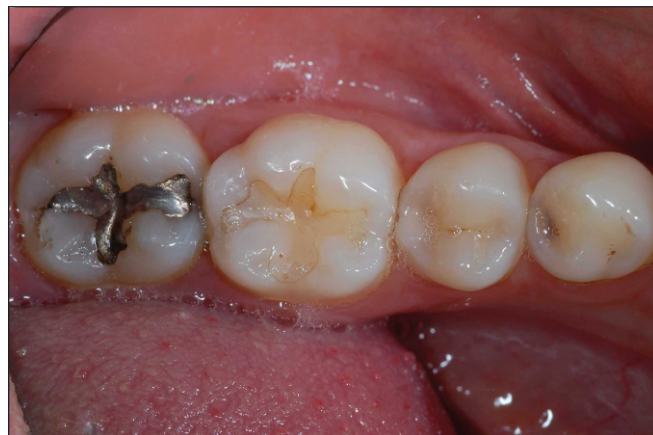

Figure 1. Pre-operative view of teeth #18-21 showing defective restorations and carious lesions.

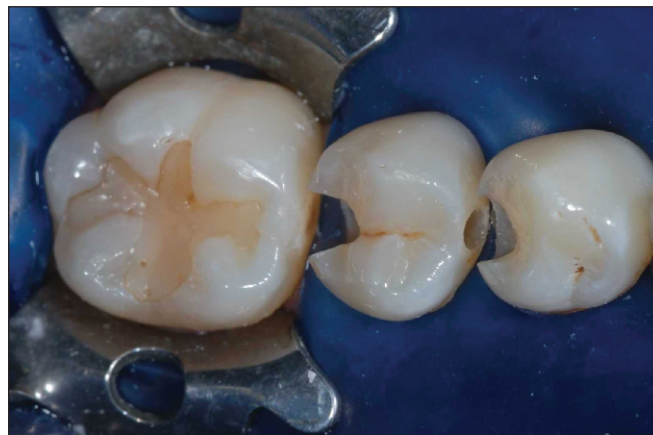

Figure 2. Cavity preparation on teeth #20 and 21 was completed; direct access to the mesial carious lesion was performed on tooth #20.

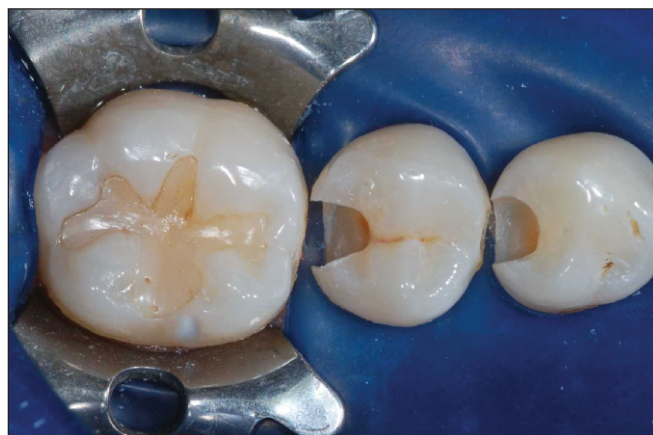

Figure 3. Occlusal view of cavity preparations showing preservation of the mesial marginal ridge on tooth #20.

to restore the mesial surface of tooth #20, following a previously described layering and curing protocol⁵ (Figure 10). The rubber dam was removed, the occlu-




Figure 4. A SuperMat matrix was modified using a dental bur.

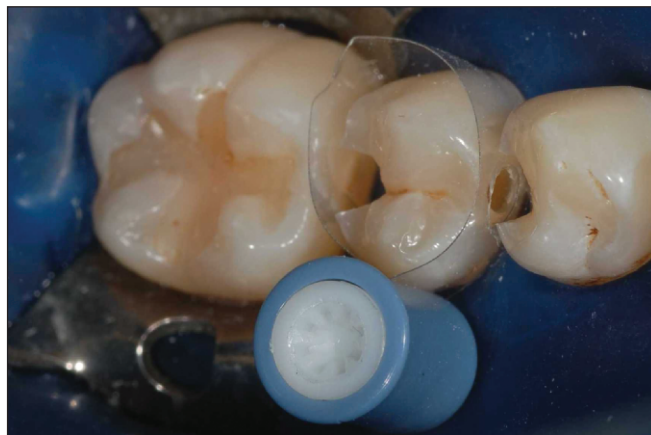

Figure 5. The modified transparent circular matrix was placed around tooth #20.

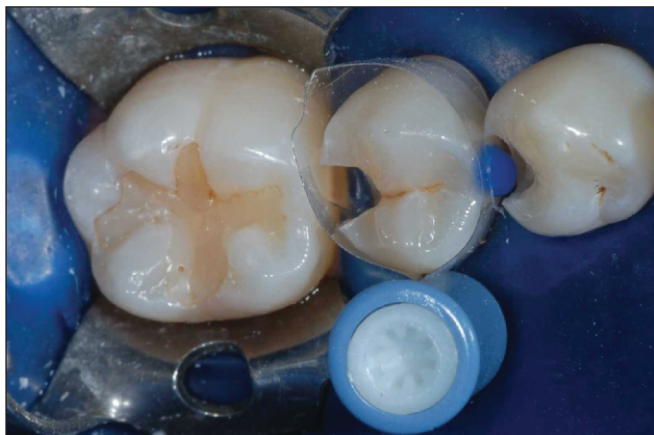

Figure 6. Etching was performed using 35% phosphoric acid.

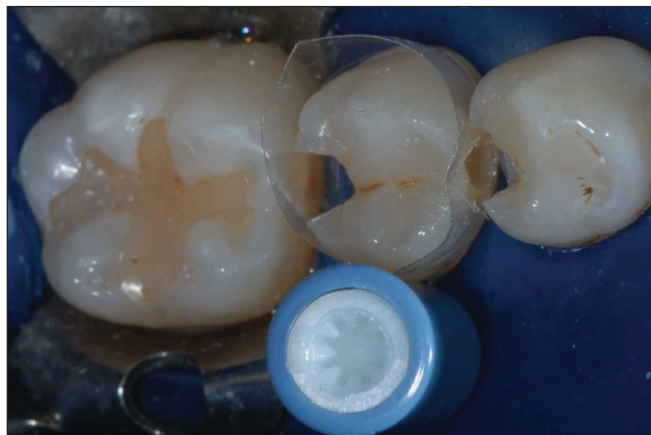

Figure 7. An ethanol-water based adhesive system was applied on both enamel and dentin.

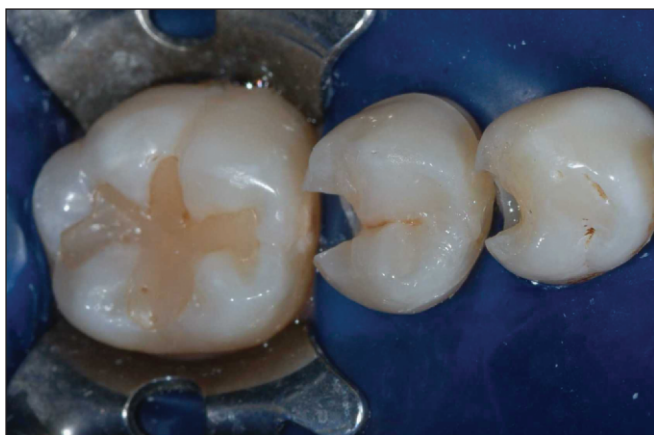

Figure 8. Final restoration of the direct access Class II restoration.

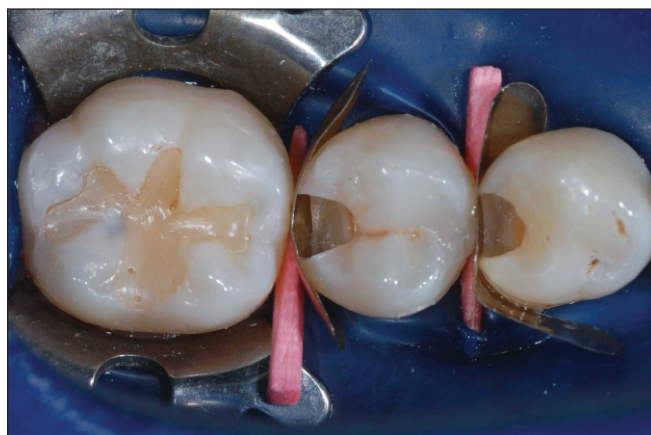

Figure 9. Sectional matrix and wooden wedges application on teeth #20 and 21.

sion checked and the restoration finished using the Ultradent Composite Finishing Kit (Ultradent Products). Initial polishing was performed with

impregnated silicon rubber cups and points, and final polishing was performed with diamond and silicon carbide impregnated cups, points and brushes (Finale

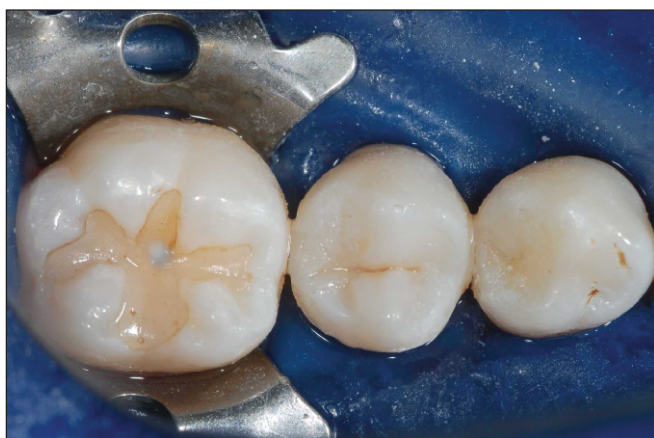

Figure 10. Once hybridization was performed, restorations were completed with the application of an A1 enamel shade to the proximal and occlusal surface and dentin shades to the remaining portion of the cavity.

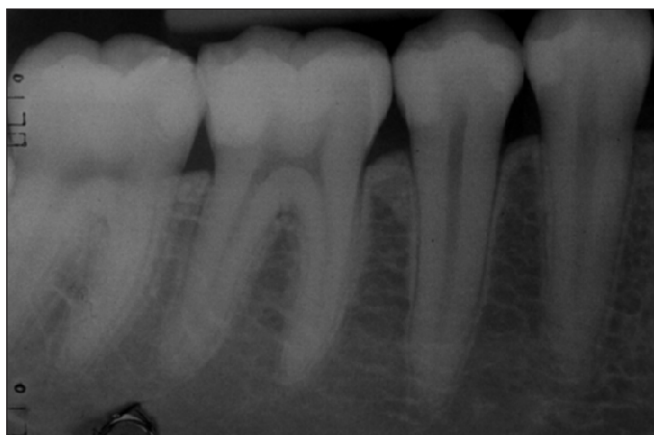

Figure 12. Post-operative radiograph showing excellent composite gingival adaptation on conventional and direct access Class II restorations.

Polishing System- Ultradent Products). The same procedure was completed for restorations on teeth #18 and #19 (Figure 11). Figure 12 shows the post-operative radiograph of the restored molar and premolars; composite gingival adaptation was achieved using both a conventional sectional matrix and modified circular matrix design.

DISCUSSION

The essence of adhesive and prophylactic dentistry is to retain the maximum amount of sound tooth structure. The preserved dental tissue contributes to the residual strength of a tooth and represents the substrate for adhesion of resin composite. The marginal ridges of posterior teeth bear functional occlusal load due to their beamlike structure. Alternatives to conventional Class II preparations have been introduced over the years to provide maximum retention of tooth structure. The tunnel preparation and the bucco-lingual slot preparation became popular in the 1980s.⁶

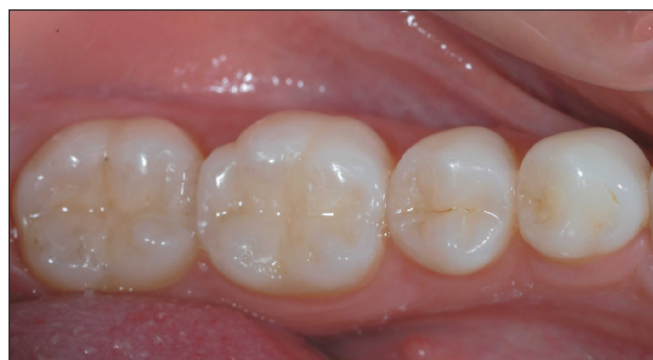

Figure 11. Post-operative occlusal view of the final restorations on teeth #18-21 at the one-week recall.

Sundberg and others⁷ and Tveit and others⁸ completed surveys regarding the preparation techniques of proximal carious lesions. These authors reported that 47%–48% of dentists prefer tunnel restorations, while 24%–32% choose saucer-shaped preparations and 20%–28% prefer traditional Class II preparations. However, the increased risk of incomplete caries removal, fracture of the marginal ridge and difficulty filling the cavity were reported when using alternative Class II preparation and restoration techniques.⁹⁻¹⁰ Wiegand and Attin¹⁰ reviewed the clinical success of tunnel restorations. A 7% to 10% annual failure rate was reported for glass-ionomer tunnel restorations; conversely, clinical studies indicate that composite tunnel restorations might be a promising alternative preparation for proximal carious lesions. The role of modern enamel-dentin adhesive systems as the primary mechanism for the reinforcement of weakened tooth structure has been stressed over the years.¹¹⁻¹²

The direct access Class II restoration technique is based on a direct proximal access approach. Proximal access does not require opening an intact occlusal surface in the marginal ridge, thus preserving sound hard tissue in a functionally sensitive area. However, this procedure is more time-consuming than a conventional MO/DO Class II restoration; increased difficulties with access for grinding, excavating and obturating similar defects should be considered. Previous research studies reported that the effectiveness of caries removal increases with increasing size of the access due to better visibility.¹³⁻¹⁴

It is worthy to note that a modified matrix design may help to avoid composite flashes and/or overhangs at the gingival and proximal margin. Careful adaptation of the matrix system is paramount to achieving this goal; the author usually selects the transparent SuperMat (KerrHawe, Orange, CA, USA) or OmniMatrix (Ultradent Products) matrix system to restore direct access Class II cavities. Overhangs have been shown to occur 25% to 76% of the time with traditional Class II restorations, resulting in gingivitis

and bone loss.¹⁵ Clinicians should also pay particular attention to the shape and size of the proximal matrix hole; the design of the matrix should be modified to allow the tip of the flowable composite syringe to contact the deepest portion of the cavity and the composite instrument to adequately condense the restorative material on both dentin and enamel. As the access to these lesions is gained through a neighboring cavity, the selection of appropriate angulated composite instruments may contribute to correct placement of the composite at the restoration cavosurface margins. The restoration of these lesions may be challenging when using regular, highly filled composite; the application of flowable composite on the deepest portion of the cavity may improve the restorative material marginal adaptation to dentin. The remaining portion of the cavity is restored using wedge-shaped increments of resin composite to be polymerized separately.⁵

The continuous development of total-etch adhesive systems¹⁶⁻¹⁷ and the improvement of resin composite physical and mechanical properties¹⁸⁻¹⁹ was responsible for a complete revolution in restorative dentistry. Minimally invasive preparations take advantage of adhesive restorations; the preservation of sound tooth structure is becoming the main goal of modern conservative dentistry.

CONCLUSIONS

Maximum conservation of residual sound tooth structure is becoming popular for both compromised teeth and initial carious lesion defects. The adhesive restoration's ability to reinforce sound tooth structure should be coupled with the selection and appropriate use of materials and techniques. A modified matrix band design may be helpful to avoid the formation of composite flash or overhang following a direct proximal approach; moreover, the marginal ridge is preserved and destruction of occlusal tooth structure avoided.

Acknowledgement

The author expresses gratitude to 3M ESPE for providing materials. The author does not have any financial interest in the companies whose materials are included in this article.

(Received 4 August 2007)

References

- Black GV (1908) *A Work on Operative Dentistry, Vol 2* Chicago: The Medico-Dental Publishing Company.
- Lasfargues JJ, Kaleka R & Louis JJ (2000) A new system of minimally invasive preparations: The Si/Sta concept. In: Roulet JF & Degrange M *Adhesion: The Silent Revolution in Dentistry* Chicago: Quintessence 107-151.
- Porte A, Lutz F, Lund MR, Swartz ML & Cochran MA (1984) Cavity designs for composite resins *Operative Dentistry* **9**(2) 50-56.
- Nordbo H, Leirskar J & von der Fehr FR (1998) Saucer-shaped cavity preparations for posterior approximal resin composite restorations: Observations up to 10 years *Quintessence International* **29** 5-11.
- Deliperi S & Bardwell DN (2002) An alternative method to reduce polymerization shrinkage in direct posterior composite restorations *Journal of the American Dental Association* **133** 1387-1398.
- Hunt PR (1984) A modified Class II cavity preparation for glass ionomer restorative materials *Quintessence International* **15** 1011-1018.
- Sundberg H, Mejare I, Espelid I & Tveit AB (2000) Swedish dentists' decisions on preparation techniques and restorative materials *Acta Odontologica Scandinavica* **58** 135-141.
- Tveit AB, Espelid I & Skodje F (1999) Restorative treatment decisions on approximal caries in Norway *International Dental Journal* **49** 165-172.
- Hugo B (2000) Preparation and restoration of small interproximal carious lesions In: Roulet JF & Degrange M *Adhesion: The Silent Revolution in Dentistry* Chicago Quintessence 153-164.
- Wiegand A & Attin T (2007) Treatment of proximal caries lesions by tunnel restorations *Dental Materials* **23**(12) 1461-1467.
- Roeters JJ (2001) Extended indications for directly bonded composite restorations: A clinician's view *Journal of Adhesive Dentistry* **3** 81-87.
- Deliperi S & Bardwell DN (2006) Clinical evaluation of cuspal coverage direct posterior composite resin restorations *Journal of Esthetic & Restorative Dentistry* **18** 256-267.
- Strand GV & Tveit AB (1993) Effectiveness of caries removal by the partial tunnel preparation method *Scandinavian Journal of Dental Research* **101** 270-273.
- Strand GV, Tveit AB & Eide GE (1995) Cavity design and dimensions of tunnel preparations versus composite resin Class-II preparations *Acta Odontologica Scandinavica* **53** 217-221.
- Brunsvold MA & Lane JJ (1990) The prevalence of overhanging dental restorations and their relationship to periodontal disease *Journal of Clinical Periodontology* **17** 67-72.
- Swift EJ Jr, Perdigão J, Wilder AD, Heymann HO, Sturdevant JR & Bayne SC (2001) Clinical evaluation of two one-bottle dentin adhesives at three years *Journal of the American Dental Association* **132** 1117-1123.
- Van Meerbeek B, Vargas M, Inoue S, Yoshida Y, Peumans M, Lambrechts P & Vanherle G (2001) Adhesives and cements to promote preservation dentistry *Operative Dentistry Supplement* **6** 119-144
- Hickel R, Manhart J & García Godoy F (2000) Clinical results and new developments of direct posterior restorations *American Journal of Dentistry* **13** 41D-54D.
- Hickel R & Manhart J (2001) Longevity of restorations in posterior teeth and reasons for failure *Journal of Adhesive Dentistry* **3** 45-64.