

Hypoplastic Enamel Treatment in Permanent Anterior Teeth of a Child

LD Carvalho • JK Bernardon • G Bruzi
MAC Andrada • LCC Vieira

Clinical Relevance

Hypoplastic enamel stain in anterior teeth can seriously compromise the esthetics of a smile. Knowing the etiology of the enamel deficiency is essential for determining the most appropriate treatment approach.

SUMMARY

In some patients with labial white stains involving the enamel and dentin, bleaching associated with a restorative procedure using composites may be an appropriate treatment alternative. Although bleaching makes the

*Luana Dutra de Carvalho, MS, PhD student, Department of Dentistry, School of Dentistry, Federal University of Santa Catarina, Florianópolis, Santa Catarina, Brazil

Jussara Karina Bernardon, MS, PhD, professor, Department of Dentistry, School of Dentistry, Federal University of Santa Catarina, Florianópolis, Santa Catarina, Brazil

Greciana Bruzi, MS, PhD student, Department of Dentistry, School of Dentistry, Federal University of Santa Catarina, Florianópolis, Santa Catarina, Brazil

Mauro Amaral Caldeira de Andrada, MS, PhD, professor, Department of Dentistry, School of Dentistry, Federal University of Santa Catarina, Florianópolis, Santa Catarina, Brazil

Luiz Clóvis Cardoso Vieira, MS, PhD, professor, Department of Dentistry, School of Dentistry, Federal University of Santa Catarina, Florianópolis, Santa Catarina, Brazil

*Corresponding author: Av. Rubens de Arruda Ramos, 2354/201, Florianópolis, Santa Catarina 88015-702, Brazil; e-mail: luanadc@hotmail.com

DOI: 10.2341/12-284-T

teeth and the stain whiter, the staining is less evident and easier to restore. Restorative procedures using adequate composites may then recover the natural optical properties while also providing appropriate mechanical properties, thereby ensuring the longevity of the treatment. In this article, the clinical case of a 9-year-old patient who reported dissatisfaction with her smile because of the presence of hypoplastic enamel staining at the central superior and inferior incisors is reported. The treatment consisted of a bleaching protocol followed by composite resin restorations using the stratification technique. The final esthetic result demonstrated the possibility of obtaining a natural smile with an adequate color and natural-looking restorations, thereby ensuring the esthetics and the patient's functional satisfaction.

INTRODUCTION

Several factors may compromise esthetics in dentistry. In the case of enamel defects, hypoplastic spots may significantly affect the smile.¹

Enamel hypoplasia results from incomplete or defective formation of the enamel organic matrix,

usually associated with genetic or environmental factors. It is a disorder caused by a dysfunction in enamel matrix secretion during the mineralization or maturation of this tissue.² When the cause of this condition is hereditary, the enamel malformations may come from defects in the genes that encode the proteins related to the mineralization process.³ Thus, when that happens, there is involvement of both the primary and secondary dentitions in a generalized way. However, when environmental factors interfere in the process, the severity of the defects is directly related to the intensity and duration of the environmental stress and with the number of affected ameloblasts.^{4,5} In those cases, the spots may be localized or generalized and may involve only enamel or enamel and dentin. Among the environmental factors that cause stains are some systemic disorders; viral diseases; nutritional deficiencies; trauma; ingestion of chemical substances, such as fluoride or some medicines; and even idiopathic causes.⁶

A dental professional must be prepared to make the right diagnosis of these changes to determine the appropriate treatment. A differential diagnosis with other lesions that cause staining should be performed, including whether the white spots came from caries lesions, trauma, or posteruption wear.¹

Adequate planning may ensure a conservative, effective, and durable treatment. Sometimes dental bleaching may be a conservative alternative, able to achieve a good result, even though many times the spots do not disappear completely.⁶ The association of abrasion with an acid occasionally improves the result.^{7, 8}

In lesions involving enamel and dentin, either with or without the loss of structure, direct restorations may be indicated. This approach may be the most conservative treatment, able to provide an excellent esthetic result and longevity. There is still the possibility of indirect restorations in more severe cases.^{1,9-12}

Among the factors to determine the appropriate treatment, the patient's age is relevant. Invasive treatments should be avoided, especially in childhood. However, when the esthetic damages compromise the child's social life, restorative treatment is indicated and should be as conservative as possible.⁹

Composite resin is a restorative material alternative that may restore esthetics with high quality, minimal wear, and durability. The necessity of whitening before providing restorative care should

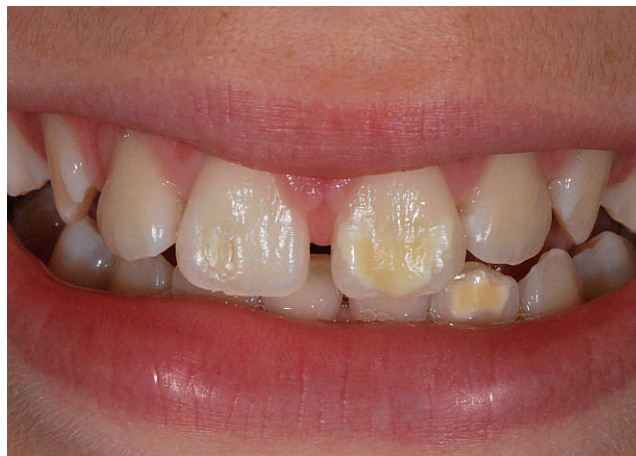

Figure 1. The patient's smile before treatment. Observe the presence of hypoplastic white spots in the anterior teeth.

be assessed in each patient, even at a young age. This procedure should be performed before restorative treatments using a low-concentration bleaching gel.

CASE REPORT

A 9-year-old female patient was unsatisfied with her smile because of the presence of white spots on the labial surface of the central incisors (Figure 1). After anamnesis and clinical examination, the teeth were diagnosed as being naturally yellow, and the white spots in the middle and incisal thirds of the upper and lower incisors (teeth 11, 21, 32) were a consequence of trauma to the deciduous teeth, in which the primary tooth injured the growing permanent tooth. The stains were characterized as hypoplastic spots. In the radiographic analysis, no periodontal or periapical alterations were observed. The enamel surface texture was not altered (Figures 2 and 3). A transilluminator device was placed on the palatal surface of each tooth to evaluate the spot depth, allowing the light transmission analysis to define the hypoplastic defects (Figure 4). Thus, it was possible to identify the depth and intensity of the alterations in the dental structures. This technique aids in the treatment approach: the less the light propagation through the affected areas, the greater the depth of the stain. Clinically this is characterized by a high degree of opacity.

The stain opacity confirmed dentin involvement in this patient, necessitating invasive treatment with direct restorations using a composite resin. The amber pigmentation around the white spot complicated the color selection. A specific bleaching protocol was indicated to minimize the yellowness

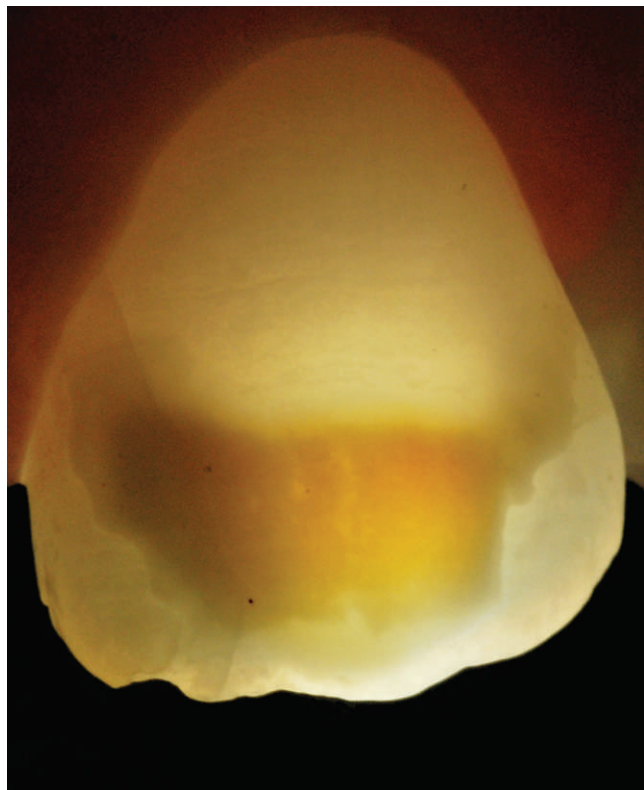


Figure 2. Using a transilluminator device placed in the palatal surface, it is possible to view the depth of staining and the degree of opacity in the teeth involved.

of the teeth and stain pigmentation. The tooth was isolated using a gingival barrier, and the 10% carbamide peroxide Whiteness Perfect 10 (FGM Produtos Odontológicos, Joinville, Brazil) was applied only to the affected area. As the patient had no sensitivity or any adverse effects, home bleaching was performed for one hour/day over a span of 14 days (Figure 5).

The mock-up of the restorations was performed seven days after completion of the bleaching. The

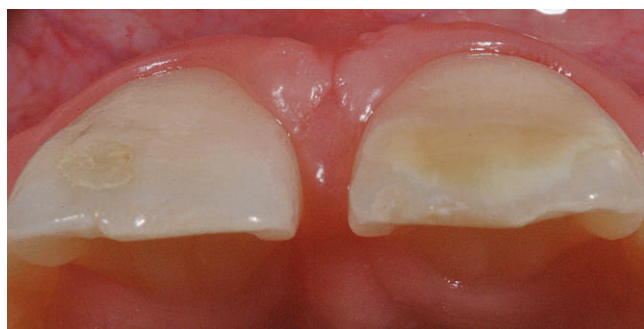

Figure 3. Incisal view of the upper central incisors. Observe that the teeth are not altered.

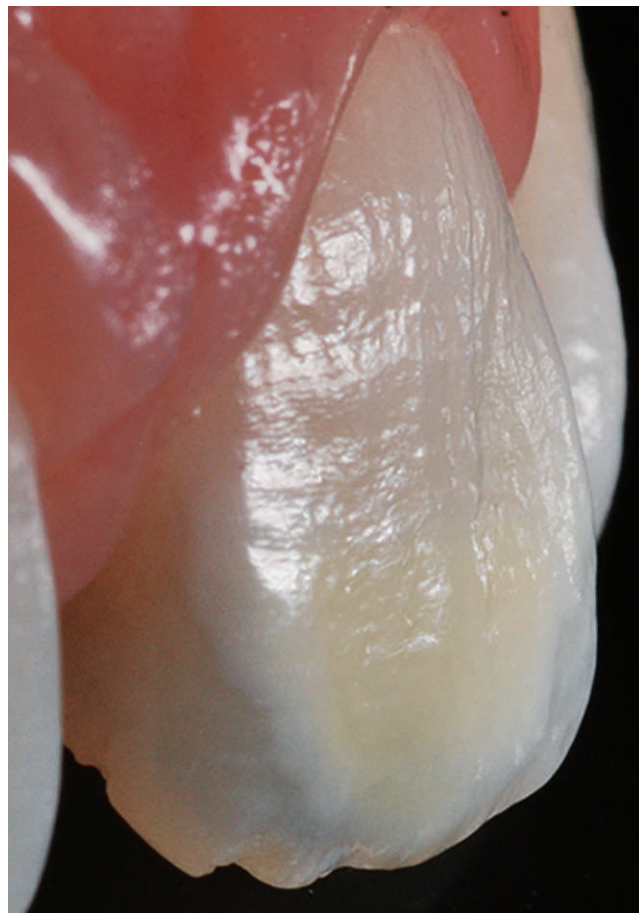


Figure 4. Proximal view of the central incisors. Note that the surface texture of the teeth is not altered.

Empress Direct Resin System (Ivoclar Vivadent, Schaan, Liechtenstein), with different levels of translucency, was selected to reproduce the optical effects of the enamel, dentin, and incisal edges.

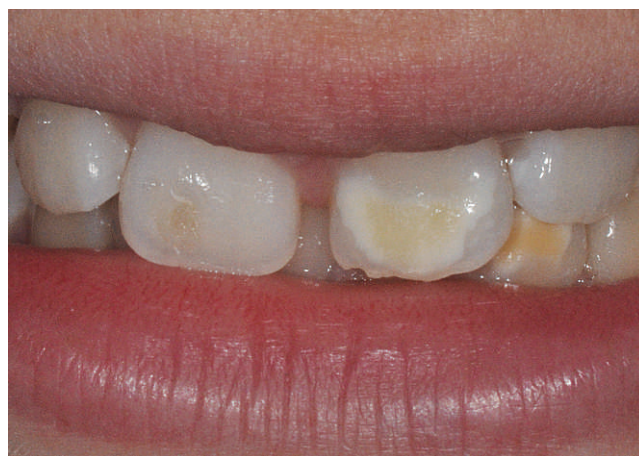

Figure 5. The upper incisors after the bleaching treatment. The home bleaching was performed only for these four teeth. Observe the increase in color homogeneity.

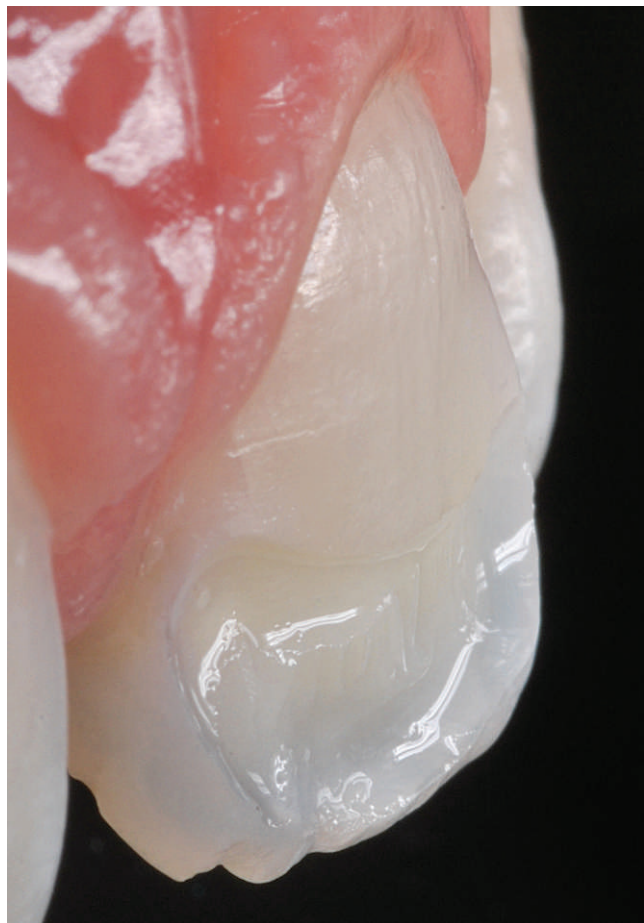

Figure 6. The proximal view demonstrates the cavity depth. Note the exposure of dentin.

After a prophylaxis, the enamel color was selected using the system scale positioned in the enamel not affected by the stain. Both the tooth and the color scale were hydrated and natural light was used.

Because the enamel macro- and microstructures were not altered, an acrylic resin matrix was made to copy the enamel surface, ensuring the reproduction of the original surface texture. This matrix was prepared by applying Vaseline (ADV Farma, São Paulo, Brazil) and saturated duralay acrylic resin spheres (Reliance Dental Mfg Co, Worth, IL, USA) on the buccal surface until autopolymerization was complete. The matrix was used at the mock-up and kept in water for the permanent treatment. The cavity was prepared using a diamond bur under water cooling. The whole depth of the hypoplastic stain was removed to eliminate the opacity difference between the affected and unaffected teeth (Figure 6). At this point, the dentin color selection was confirmed and the opalescent shade was selected.

The mock-up was conducted with the selected shades for each layer. Hybridization of dental tissues was performed only at one point at this time. After three days, the color restoration was observed to be correct, allowing the buildup of the final restorations.

The mock-up was removed and the rubber dam was used to restore definitely. The cavity was etched with 37% phosphoric acid for 15 seconds on dentin and 30 seconds on the enamel, extending 1 mm beyond the preparation margins. After rinsing, the dentin was protected with a cotton pellet and the enamel was air-dried. The adhesive system Single Bond 2 (3M ESPE, St Paul, USA) was applied, following the manufacturer's instructions, taking care to remove any excess, especially in the proximal surfaces. The cavity was photocured for 10 seconds.

The restoration was fabricated with composite resins from the Empress Direct kit (Ivoclar Vivadent, Schaan Liechtenstein). For the reconstruction of the artificial dentin, the shade A1D was used at the cavosurface angle associated with the shade B1D applied on the bottom of the cavity. The same composite resin was used to sculpt the dentinal mamelons. This layer was light polymerized for 40 seconds. To reproduce the opalescent effect, the shade trans-opal was placed over the tips of the mamelons, between the dentin composite and the incisal edge. This layer was light-polymerized for 40 seconds. The enamel was reproduced with a high translucent composite resin for bleaching teeth (shade EBL-L). A brush was used to smooth and adapt the composite at the cavosurface margins. Liquid Vaseline was applied on the inner surface of the acrylic matrix, which was placed on the restoration surface. The excess was removed, and the assembly was polymerized for 40 seconds. The enamel surface was adequately reproduced. The photo-polymerization was completed without the matrix.

The procedure was repeated for the other spots. After 24 hours, the surfaces were polished with flexible discs and rubber points. The natural tooth structure was successfully reproduced with the restorations (Figures 7 and 8).

DISCUSSION

Hypoplastic white spots on permanent teeth may be a result of several factors. In the clinical case reported, trauma with the deciduous dentition during the formation of the permanent tooth enamel likely caused the stains on the permanent teeth.

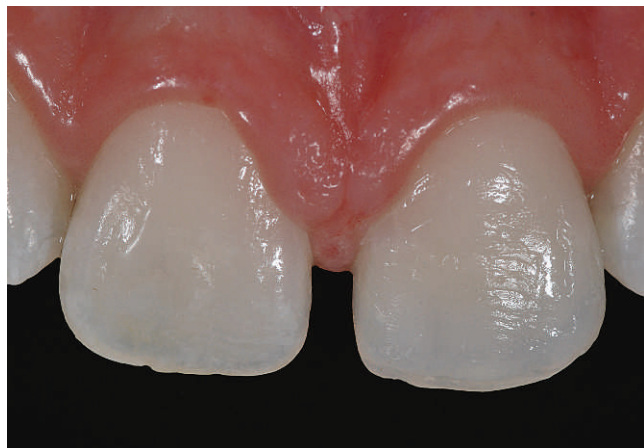

Figure 7. The final restorations.

Such accidents, relatively common in the first dentition, mainly at the incisors, can cause defects on the surfaces of the permanent successors.^{13,14} These stains presented an increased opacity and an amber pigmentation in the contour but no changes in the surface texture.

When localized to the anterior teeth, hypoplastic stains may have psychological and behavioral consequences as a result of the esthetic changes. This may influence the social life of the patient, as the defects alter the tooth structure and affect the appearance of the smile.⁹

It is known that some cosmetic procedures should be avoided and the invasive treatment of these defects should be postponed. However, the stains in the patient described here were generating great dissatisfaction, as the patient wanted to be a model. In less severe cases, bleaching could generate good results. Nevertheless, the enamel and dentin involvement was decisive for choosing the restorative treatment. The teeth had already completed eruption, an essential factor for the procedure.⁶ Therefore, the composite restoration was chosen to be the more conservative option because it is associated with excellent mechanical, esthetic, and functional properties. However, the imminent difficulty in achieving perfect esthetics because of the amber pigmentation at the stain margin indicated the need for bleaching. In pediatric patients, it is known that a bleaching treatment should follow the policy determined by the American Association of Pediatric Dentistry (AAPD), which has defined the judicious use of bleaching for vital and nonvital teeth in children.

The procedure must be strictly controlled by the dentist, who should determine the appropriate method and timing of the treatment within the

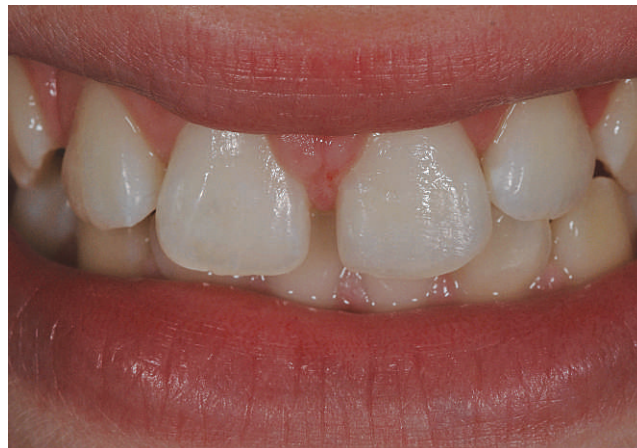

Figure 8. The final smile.

context of an individualized, comprehensive, and sequenced planning, while also considering the side effects of tooth whitening for children and adolescents. The AAPD does not indicate the total arch treatment for patients with mixed dentition.¹⁵ Taking into account that a young patient's pulp is wider than that of an adult patient, and that the diffusion of hydrogen peroxide at high concentrations into dental tissues is extensive,¹⁶⁻¹⁸ a safer treatment was selected for the current patient: 10% carbamide peroxide, reducing the possibility of sensitivity.¹⁹⁻²¹ This treatment was performed in an individualized way for this patient: using direct applications on the more pigmented areas followed by application with personal trays for 14 days, and only with the affected teeth.

The mock-up was performed to ensure predictability of the result. By using the stratification technique,^{22,23} the opaque shades restored the affected dentin and reconstructed anatomical structures, such as dentin mamelons. The characteristics of the natural dentition colors could be reproduced with the effect shades, reproducing the translucency of the incisal edge, which generally reflects a blue or gray color. When applied on the dentin composite, the incisal edge shade generates a counter-opalescent effect, reflecting an orange hue. A translucent composite was applied on the surface. It is important to consider that, during stratification with composites, the resin enamel thickness must be thinner than the natural enamel to prevent a reduction in the restoration value. Thicker layers of enamel resin generate more gray restorations because of the difference of the refractive index between the resin and the natural tooth.²⁴ Therefore, each step of the treatment is essential for a successful outcome: diagnosis, planning, and execution.

CONCLUSION

In the cases of hypoplastic spots on anterior teeth, in which color change and increased opacity affect the smile, the use of a combined treatment of bleaching and composite resin restorations can improve the appearance and uniformity of the teeth, restoring the patient's self-esteem. A correct diagnosis of the lesion depth is necessary for proper planning and to ensure a predictable outcome and success in the short and long term.

Conflict of Interest

The authors of this article certify that they have no proprietary, financial, or other personal interest of any nature or kind in any product, service, and/or company that is presented in this article.

(Accepted 10 September 2012)

REFERENCES

- Bernardon JK, Gondo R, & Baratieri LN (2011) Minimally invasive restorative treatment of hypoplastic enamel in anterior teeth *American Journal of Esthetic Dentistry* **1**(1) 2-13.
- Clarkson Seow WK (1997) Clinical diagnosis of enamel defects: pitfalls and practical guidelines *International Dental Journal* **47**(3) 173-182.
- Simmer JP, & Hu JC (2001) Dental enamel formation and its impact on clinical dentistry *Journal Dental Education* **65**(9) 896-905.
- Elcock C, Smith RN, Simpson J, Abdellatif A, Bäckman B, & Brook AH (2006) Comparison of methods for measurement of hypoplastic lesions *European Journal of Oral Sciences* **114** (Supplement 1) 365-369.
- Witzel C, Kierdorf U, Schultz M, & Kierdorf H (2008) Insights from the inside: histological analysis of abnormal enamel microstructure associated with hypoplastic enamel defects in human teeth *American Journal of Physical Anthropology* **136**(4) 400-414.
- Ribas AO, & Czulsiak GD (2004) Anomalies in dental enamel: etiology, diagnostic and treatment *Publicações da UEPG Ciências Biológicas e da Saúde* **10**(1) 23-36.
- Chhabra N, & Singbal KP (2010) Viable approach to manage superficial enamel discoloration *Contemporary Clinical Dentistry* **1**(4) 284-287.
- Nahsan FP, da Silva LM, Baseggio W, Franco EB, Francisconi PA, Mondelli RF, & Wang L (2011) Conservative approach for a clinical resolution of enamel white spot lesions *Quintessence International* **42**(5) 423-426.
- Bendo CB, Sacarpelli AC, Junior JBNVale MPP, Paiva SM, & Pordeus IA (2007) Enamel hypoplasia in permanent incisors: a six-month follow-up *Revista Gaucha de Odontologia* **55**(1) 107-112.
- Reston EG, Corba DV, Ruschel K, Tovo MF, & Barbosa AN (2011) Conservative approach for esthetic treatment of enamel hypoplasia *Operative Dentistry* **36**(3) 340-343.
- Nixon PJ, Robinson S, Gahan M, & Chan MF (2007) Conservative aesthetic techniques for discoloured teeth: 2. Microabrasion and composite *Dental Update* **34**(3) 160-162.
- Khatri A, & Nandlal B (2010) An indirect veneer technique for simple and esthetic treatment of anterior hypoplastic teeth *Contemporary Clinical Dentistry* **1**(4) 288-290.
- de Amorim LF, da Costa LR, & Estrela C (2011) Retrospective study of traumatic dental injuries in primary teeth in a Brazilian specialized pediatric practice. *Dental Traumatology* **27**(5) 368-373.
- American Academy on Pediatric Dentistry Council on Clinical Affairs (2008-2009) Policy on dental bleaching for child and adolescent patients *Pediatric Dentistry* **30**(Supplement 7) 61-63.
- Carvalho V, Jacomo DR, & Campos V (2010) Frequency of intrusive luxation in deciduous teeth and its effects *Dental Traumatology* **26**(4) 304-307.
- Trindade FZ, Ribeiro AP, Sacono NT, Oliveira CF, Lessa FC, Hebling J, & Costa CA (2009) Trans-enamel and trans-dentinal cytotoxic effects of a 35% H₂O₂ bleaching gel on cultured odontoblast cell lines after consecutive applications *International Endodontic Journal* **42**(6) 516-524.
- Dias Ribeiro AP, Sacono NT, Lessa FC, Nogueira I, Coldebella CR, Hebling J, & de Souza Costa CA (2009) Cytotoxic effect of a 35% hydrogen peroxide bleaching gel odontoblast-like MDPC-23 cells *Oral Surgery, Oral Medicine, Oral Pathology, Oral Radiology and Endodontics* **108**(3) 458-464.
- Dantas CM, Vivan CL, Ferreira LS, Freitas PM, & Marques MM (2010) In vitro effect of low intensity laser on the cytotoxicity produced by substances released by bleaching gel *Brazilian Oral Research* **24**(4) 460-466.
- Heymann HO (2005) Tooth whitening: facts and fallacies *British Dental Journal* **198**(8) 514.
- Cardoso PC, Reis A, Loguercio A, Vieira LC, & Baratieri LN (2010) Clinical effectiveness and tooth sensitivity associated with different bleaching times for a 10 percent carbamide peroxide gel *Journal of American Dental Association* **141**(10) 1213-1220.
- Li Y (2011) Safety controversies in tooth bleaching *Dental Clinics North America* **55**(2) 255-263.
- Ardu S, & Krejci I (2006) Biomimetic direct composite stratification technique for the restoration of anterior teeth *Quintessence International* **37**(3) 67-74. Erratum in: **37**(5) 408.
- Pontons-Melo JC, Furuse AY, & Mondelli J (2011) A direct composite resin stratification technique for restoration of the smile *Quintessence International* **42**(3) 205-211.
- Schmeling M, Andrada MA, Maia HP, & Araújo EM (2012) Translucency of value resin composites used to replace enamel in stratified composite restoration techniques *Journal of Esthetic and Restorative Dentistry* **24**(1) 53-58.