

# Proximal Box Elevation With Resin Composite and the Dogma of Biological Width: Clinical R2-Technique and Critical Review

C Frese • D Wolff • HJ Staehle

## Clinical Relevance

Advancements in material technology and clinical techniques led to increasing indications for minimally invasive treatment approaches with direct resin composite restorations. Proximal box elevation, an example of an elaborate clinical technique, provides a two-step procedure for the restoration of deep and undermining defects in the proximal area.

## SUMMARY

**Provided that moisture control is possible, today's resin composite materials can be applied successfully in the restorative treatment of extensively decayed teeth. This suggests that restorative margins will be increasingly located below the cemento-enamel junction, probably invading biological width. The re-**

**cently introduced technique of proximal box elevation (PBE) offers the possibility of performing a stepwise elevation of deep proximal cavities to create more favorable preparation margins for direct or indirect restorations. Clinical instructions for the restoration of extensively damaged teeth are given through this presentation. A two-step R2-technique will be shown, and a critical review of the dogma of biological width will be presented.**

\*Cornelia Frese, Dr. med. dent., senior dentist, University Hospital Heidelberg, Department of Conservative Dentistry, Heidelberg, Germany

Diana Wolff, Dr.med.dent, University of Heidelberg, Department of Conservative Dentistry, Heidelberg, Germany

Hans Joerg Staehle, Prof.Dr.med., Dr.med.dent., head of department, University of Heidelberg, Department of Conservative Dentistry, Heidelberg, Germany

\*Corresponding author: Im Neuenheimer Feld 400, Heidelberg, 69120, Germany; e-mail: cornelia.frese@med.uni-heidelberg.de

DOI: 10.2341/13-052-T

## INTRODUCTION

With current adhesive technology and modern composite resin materials it has become possible to restore even severely damaged teeth. Thus, minimally invasive techniques are used to save a maximum amount of sound tooth substance.<sup>1</sup> Even extensive and undermining tooth defects can be restored using direct composite resin materials. In general, it is recommended that the cervical margin

of the restoration should be placed within an intact enamel layer. However, provided that moisture control is possible, composite resin restorations can be applied successfully in deeper cavities, even when restorative margins are located below the cemento-enamel junction (CEJ).<sup>2</sup> A new operational range is thus opened up as the composite resin is located subgingivally adjacent to the junctional epithelium and alveolar bone crest. Modern application techniques allow for the creation of planned and nonirritating composite resin margins in this area.<sup>3,4</sup> A recently described technique, proximal box elevation (PBE), offers the possibility of a stepwise relocation of deep proximal margins to uplift cavity outlines for direct or indirect restorations.<sup>5,6</sup> Step one (PBE) involves a meticulous layering technique for margin relocation above the CEJ. Step two allows the practitioner to decide on whether to place a direct or indirect restoration under improved clinical conditions.

Before restoring extensively decayed teeth, the distance between the future restorative margin and the alveolar crest should be evaluated carefully, for example, by bone sounding. An adequate space for restorative margin placement can be achieved by surgical (crown lengthening procedure) or orthodontic treatment (forced eruption).<sup>7</sup>

The physiological dimensions of the dentogingival junction, with its inherent parts of epithelial attachment, connective tissue attachment, and sulcus depth, were first described by Gargiulo and others in 1961<sup>8</sup> and reevaluated by Vacek and others in 1994.<sup>9</sup> Gargiulo and others described the ideal dimension of the dentogingival junction to be 2.73 mm and Vacek and others determined it to be 3.25 mm.<sup>9</sup> Based on these reports, a distance of 3 mm and more is recommended between restorative margins and the alveolar crest to avoid detrimental effects on neighboring soft and hard tissues.<sup>10-13</sup> In restorative terminology this distance is generally called "biological width."

Violations of the biological width resulting from intracrevicular placement of restorative margins can result in severe gingival inflammation,<sup>4</sup> loss of periodontal attachment, and bone resorption.<sup>11,15</sup> Furthermore, marginal overhangs of direct and indirect restorations are related closely to elevated plaque accumulation, microbiological diversification, and increasing chronic inflammation of soft and hard tissue.<sup>16</sup>

Clinical observations in our department revealed that plain, smooth, and nonirritating margins on

deep occluso-proximal resin composite restorations invading biological width are free of gingival and periodontal inflammation, provided that there is distinct oral hygiene training and use of accurately fitting interdental brushes. This fact leads to the hypothesis that subgingival composite resin restorations fabricated using a two-step R2-technique may violate the area of biological width without inducing chronic inflammation.

Together with the clinical procedure presented here, a stepwise introduction is given to the restoration of extensively damaged teeth by applying a direct composite resin restoration, using the two-step R2-technique (step one: PBE; step two: direct composite resin restoration). Furthermore, a critical review is given on the consistency of the dogma of biological width.

## CLINICAL TECHNIQUE

### Patient Presentation

A 75-year-old female psychologist visited the Department of Conservative Dentistry, Clinic for Oral, Dental and Maxillofacial Diseases, University Hospital Heidelberg, with a restoration loss on the mandibular right premolar #45. A review of her medical history revealed no medical disease. She was a nonsmoker and took no medications. She stated that she felt no pain on tooth #45. Clinical examination revealed positive vitality, no tooth mobility, and probing depths of 2 mm.

Intraoral evaluation revealed carious decay on the cervical margin of the cavity reaching beyond the CEJ. The proximal margin was partly covered by overgrowing gingival tissue (Figure 1). Radiographic examination of tooth #45 revealed that there was no periapical translucency and that the distance between the cavity margin and the alveolar bone crest was between 0.5 mm and 1.0 mm (Figure 2). As the proximal cavity margin was already beyond the CEJ invading biological width, it was assumed that after caries removal it would be located at the level of the alveolar crest. It was explained to the patient that the gold-standard treatment would be placement of an indirect partial or full crown in combination with surgical or orthodontic pretreatment. Alternatively, it was clarified that if the marginal ridge was still intact, a direct restoration with composite resin could be an option. However, it was also explained that the outcome of this procedure would be less predictable than that of an indirect restoration. The patient favored a restoration with direct composite resin to avoid surgical or orthodontic interventions.

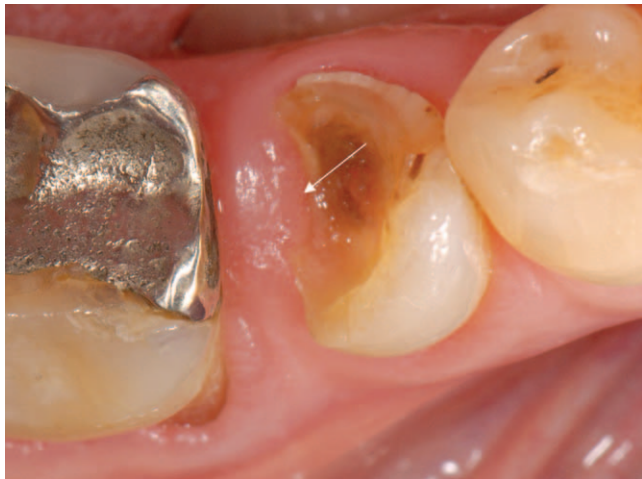

Figure 1. Preoperative view of tooth #45 with occluso-proximal decay and loss of restoration a few weeks before R2-technique was performed. Gingival overgrowth is seen on proximal cavity margin (arrow).

Description of the R2-Technique

**Step One (PBE)**—All materials used are listed in Table 1. After local anesthesia, the excessive gingiva was removed using an electrosurgical unit (Elektrotom MD 62, KLS Martin GmbH & Co KG, Tuttlingen, Germany). Caries was removed with a bur (H1SEM 204.018-23, Komet, Gebr. Brasseler GmbH & Co.KG, Lemgo, Germany), and any sharp

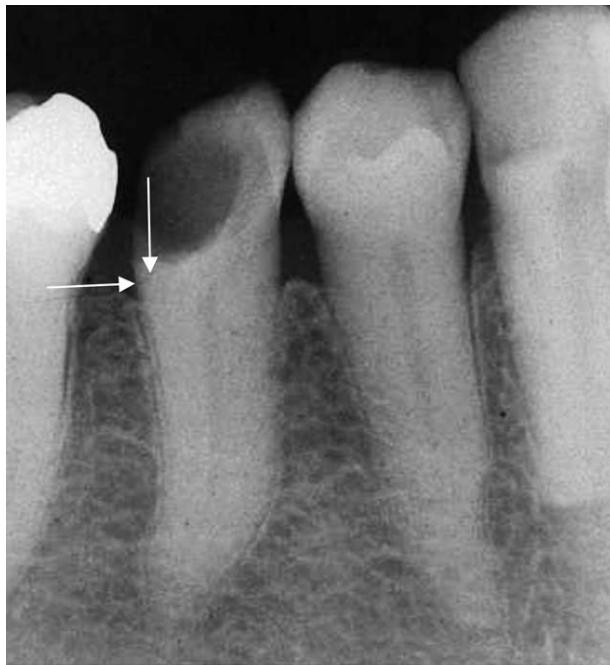

Figure 2. Preoperative x-ray of tooth #45. After excavation of caries, the proximal cavity margin is located close to the alveolar crest (arrow).

Table 1: Table of materials used for R2-technique	
Material	Manufacturer
Electrosurgical unit	Elektrotom MD 62, KLS Martin GmbH & Co KG, Tuttlingen, Germany
Rotary instruments H1SEM 204.018-23, #128-130	Komet, Gebr. Brasseler GmbH & Co.KG, Lemgo, Germany
Astringent retraction paste	Astringent Retraction Paste, 3M ESPE, Seefeld, Germany
Adhesive system	Optibond FL, Kerr, Orange, CA, USA
Flowable composite	Tetric Evo Flow, Ivoclar Vivadent, Schaan, Liechtenstein
Restorative resin composite	Tetric Evo Ceram, Ivoclar Vivadent, Schaan, Liechtenstein
Rubber dam	Hygienic Dental Dam, Coltene Whaledent, Langenau, Germany
50 µm Al <sub>2</sub> O <sub>3</sub> powder	Kaltenbach & Voigt, Biberach, Germany
Sectional matrix system	Palodent, Dentsply DeTrey, Konstanz, Germany
Proximal contact instrument	OptraContact, Ivoclar Vivadent, Schaan, Liechtenstein
Polishing kit	Astropol HP, Ivoclar Vivadent, Schaan, Liechtenstein
Interdental brush	CPS 14 Z, Curaden International AG, Amlehnstrasse 22, 6010 Kriens, Schweiz

angles were rounded. At this point, it was clear that the proximal cavity margin was close to the alveolar crest, making the application of a partial or circular matrix impossible (Figure 3). For hemostasis, a retraction cord was placed and an astringent paste was applied for 2 minutes and rinsed carefully (Astringent Retraction Paste, 3M ESPE, Seefeld, Germany) (Figure 4). Afterward, direct composite resin was applied to perform a PBE in accordance with the protocol of Frankenberger and others<sup>5</sup> and Roggendorf and others<sup>6</sup> (Figure 5). Tooth #45 was etched for 15 seconds with 37% phosphoric acid, a filled ethanol-based adhesive system (Optibond FL, Kerr, Orange, CA, USA) was applied and the adhesive was light-polymerized for 20 seconds (Bluephace C8, Ivoclar, Vivadent, Schaan, Liechtenstein). A thin layer of flowable composite resin (Tetric Evo Flow, Ivoclar Vivadent) was placed on the cavity margin. On top of the nonpolymerized layer of flowable resin, another layer of viscous composite resin was applied (Tetric Evo Ceram, Ivoclar Vivadent). The viscous material was molded and gently pressed into the flowable resin (Snowplough Technique, Figure 6 detailed description vide infra).<sup>17</sup> Final polymerization of both the flowable and the viscous composite resin was then completed with light at 800 mW/cm<sup>2</sup> (40 seconds). Because of the



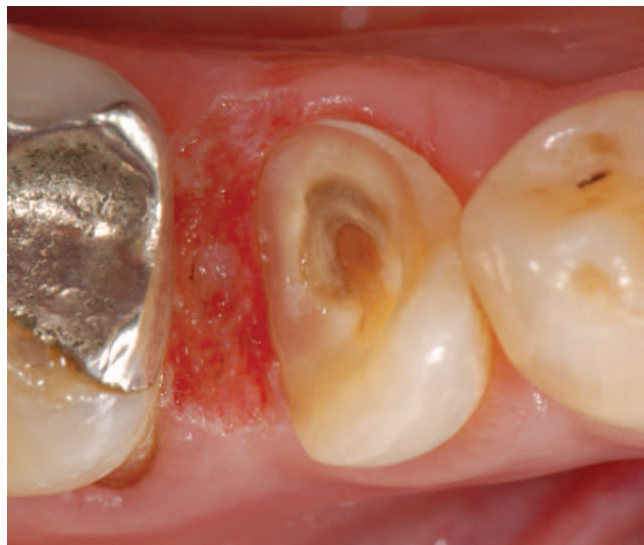

Figure 3. R2-technique: Placement of a direct resin composite restoration in the two-step technique. Step one (PBE): Clinical situation after gingivectomy (Elektrotom) and caries excavation. The proximal cavity margin is located below the CEJ next to the alveolar crest.

abandonment of a matrix, marginal overhangs could not be avoided. Subsequently, they were removed carefully with a rotary diamond instrument #128-130 (Flamme 128-130; Komet, Gebr. Brasseler GmbH & Co.KG) and a scalpel (Figure 7a).

*Step Two (direct composite resin restoration)*—A rubber dam (Hygienic Dental Dam, Coltene Whale-dent, Langenau, Germany) was placed, and the previously placed PBE was cleaned carefully and

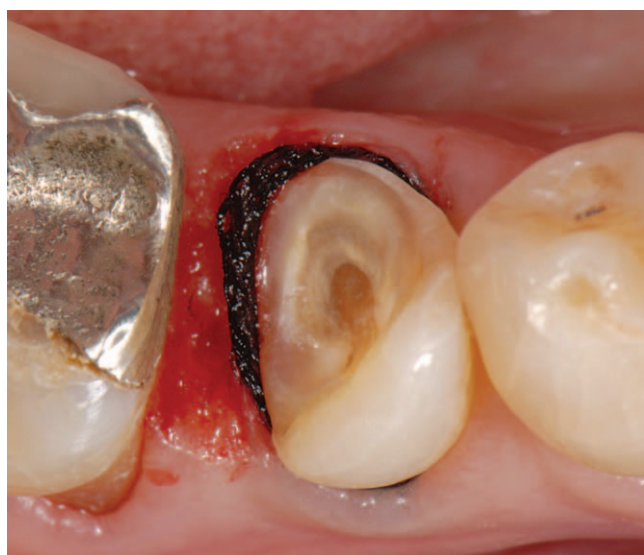

Figure 4. Application of a retraction cord. The cord could not be inserted fully into the sulcus because of the proximity of the alveolar crest. Subsequently, an astringent paste was applied for 2 min.

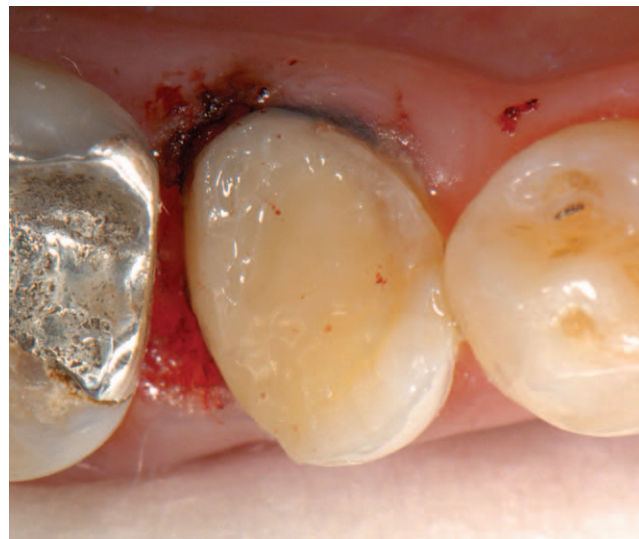

Figure 5. After etching, priming, and bonding, a layer of flowable composite was placed meticulously on the cavity margin, followed by a layer of viscous resin composite (both unpolymerized). After modeling and shaping both materials, the final light polymerization was carried out (Snowplough technique).

roughened by  $\text{Al}_2\text{O}_3$  powder (50  $\mu\text{m}$ , Kaltenbach & Voigt, Biberach, Germany). A sectional matrix (Palodent, Dentsply DeTrey, Konstanz, Germany) was inserted and fixed with a wedge and a separation ring. Between the PBE placed in step one and the sectional matrix, a narrow and sharp angled junction occurs. Etching and bonding steps were carried out using the same materials described previously.

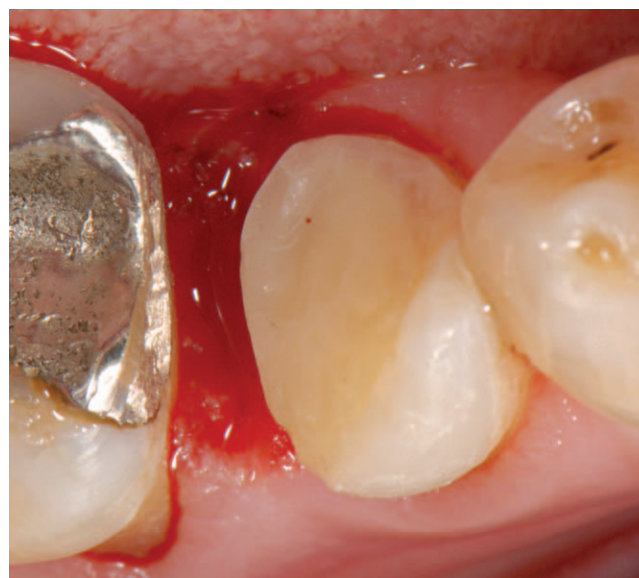

Figure 6. Schematic drawing of Snowplough technique: Note that in clinical practice there is a narrow and sharp angled junction between PBE placed in step one and the sectional matrix.

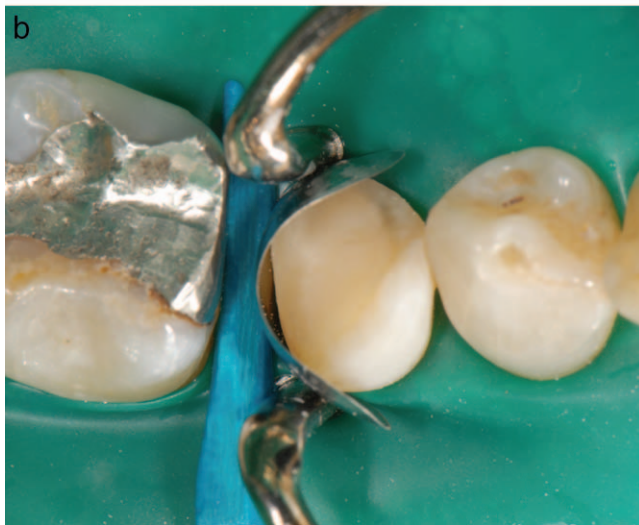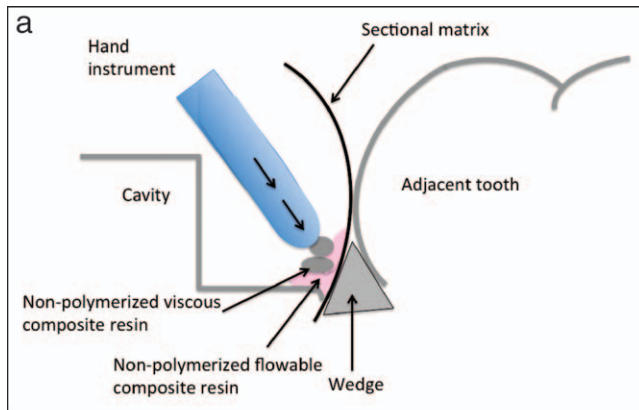


Figure 7. (a) Clinical situation after the PBE. The subgingival restorative margin was finished with rotary diamond instruments and a scalpel to remove overhangs and to create a smooth, planed, and nonirritating surface. (b) Step two: Occlusal view after application of the rubber dam, subsequent sandblasting with aluminium oxide, placement of a sectional matrix, wedging, and application of a separation ring.

The composite resin was applied using the Snowplough technique (Figure 6).

A small amount of flowable composite resin (Tetric Evo Flow, Ivoclar Vivadent) was applied on the bottom of the cavity and gently dispersed with a dental probe for nonporous adaptation. The non-polymerized flowable resin should cover the sharp angled junction between the cavity margin and sectional matrix completely. On top of the non-polymerized layer of flowable resin, small amounts of viscous composite resin were applied (Tetric Evo Ceram, Ivoclar Vivadent) and gently pressed into the flowable resin using a hand instrument. In this way, the composite resin was adapted tightly to the cavity surface, resulting in a nonporous restoration–tooth interface.

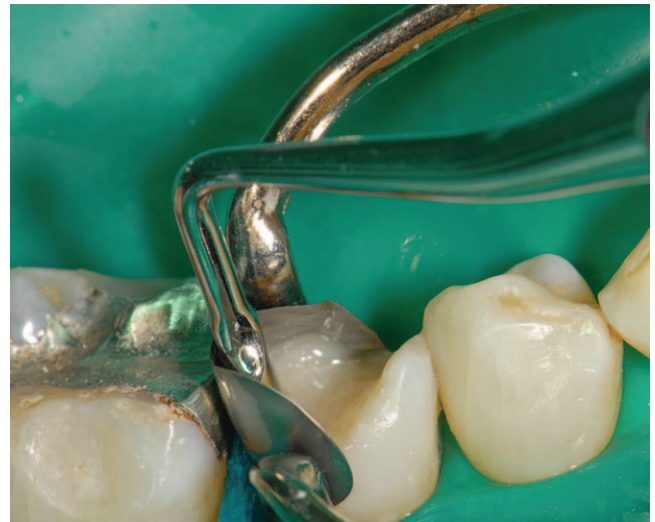

Figure 8. Composite resin is applied using the Snowplough technique. To obtain a tight proximal contact, a special hand instrument was used to separate the teeth during light polymerization.

To obtain a tight proximal contact, a special hand instrument (OptraContact, Ivoclar Vivadent) was used (Figures 8 and 9). Final polymerization of both the flowable and the viscous composite resin was then completed with light at  $800 \text{ mW/cm}^2$  (40 seconds). Finally, the rubber dam was removed, the occlusion was checked, and the restoration was finished using the Astropol HP Finishing Kit (Astropol HP, Ivoclar Vivadent) (Figures 7b through 10). After the treatment session, the patient underwent oral hygiene training, and accurately fitting interdental brushes were chosen (Figure 11).

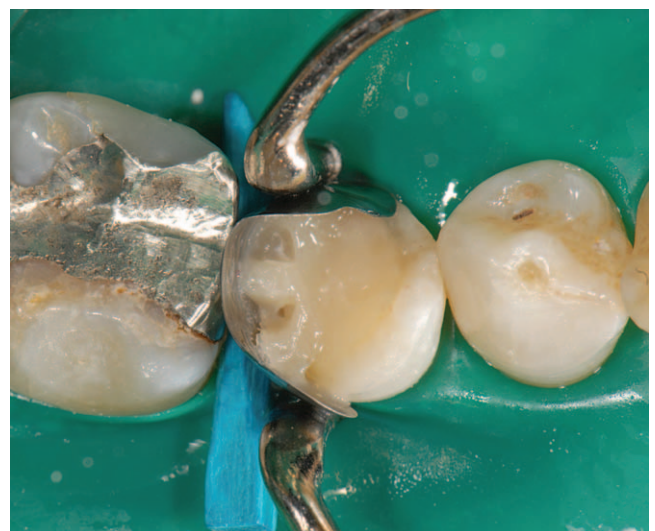

Figure 9. Occlusal view after removal of the proximal contact instrument. A tight proximal contact to the adjacent tooth is accomplished.



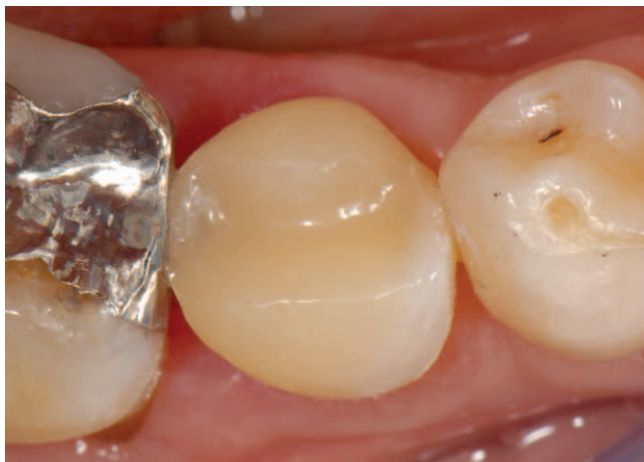

Figure 10. Clinical situation after removal of the rubber dam.

The postoperative radiographic examination of tooth #45 revealed that the proximal cavity margin was located adjacent to the alveolar bone crest and in close contact to connective tissue fibres of the dentogingival complex (distance 0.5–1.0 mm) (Figure 12).

**12-Month Recall**—The clinical observation after 12 months revealed a vital tooth #45 with no inflammatory signs in the surrounding soft and hard tissue (Figure 13). Despite the fact that the biological width was clearly violated, the probing depths were 2 mm, and no bleeding occurred on probing (Figure 14). Radiographic examination revealed a distance of 1 mm between the restorative margin and the alveolar

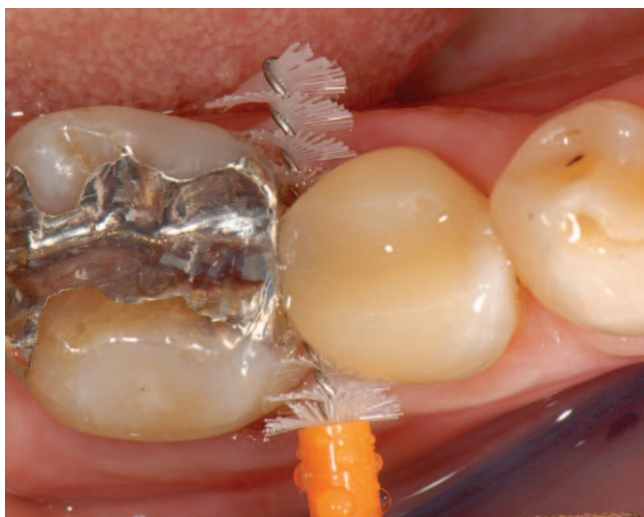

Figure 11. Postoperative view showing the selection of an accurately fitting interdental brush.

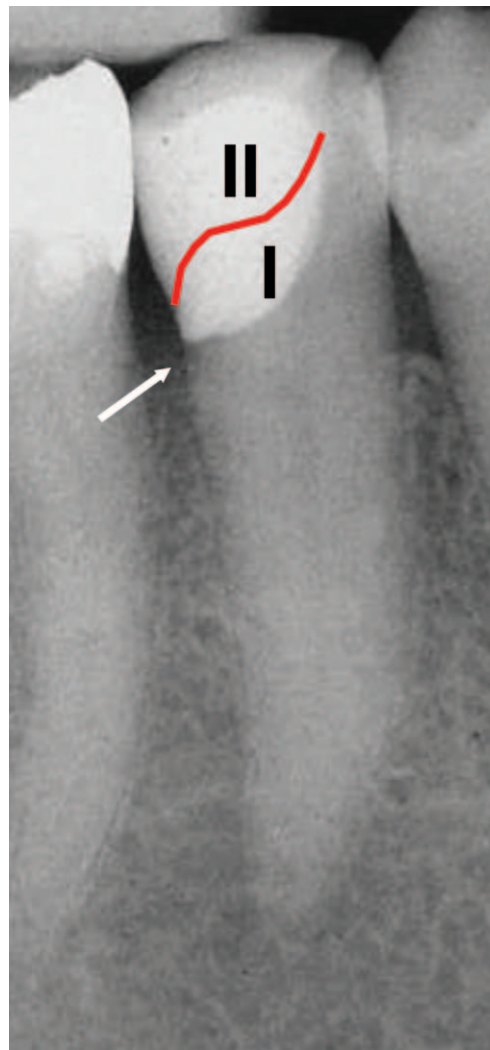


Figure 12. Postoperative x-ray of tooth #45. The subgingival restorative margin invades the biological width (the distance between restorative margin and alveolar crest was 0.5–1.0 mm). The emergence profile of the direct composite resin restoration is anatomically correct. The first part of the R2-restoration (PBE) merges continuously into the second part of the restoration

crest. Over the 12-month period, only a minimal loss of alveolar bone was observed (Figure 15).

## DISCUSSION

Successful and long-term composite resin restoration of cavities reaching below the CEJ is only possible if adequate moisture management is possible. During the first step of the presented two-step R2- technique, the complex problem of moisture management and restoration accomplishment is reduced to the circumscribed area of the proximal box. In this comparatively small area of the tooth, contamination is easier to handle and prevent, even if no rubber

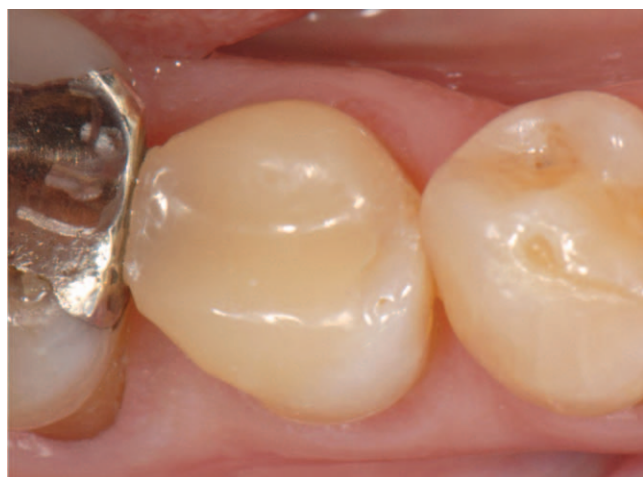

Figure 13. Clinical situation after 12 months: occlusal view.

dam is placed. After this critical part of the cavity is taken care of separately, a rubber dam can be placed much easier in step two of the restorative procedure, as described previously.<sup>5</sup>

The Snowplough technique contributes essentially to achieving a homogenous and nonporous restoration-tooth interface. It is described as the combined use of a flowable composite and a viscous composite resin molded together in an unpolymerized state, followed by final polymerization of both materials (Figure 6).<sup>17</sup>

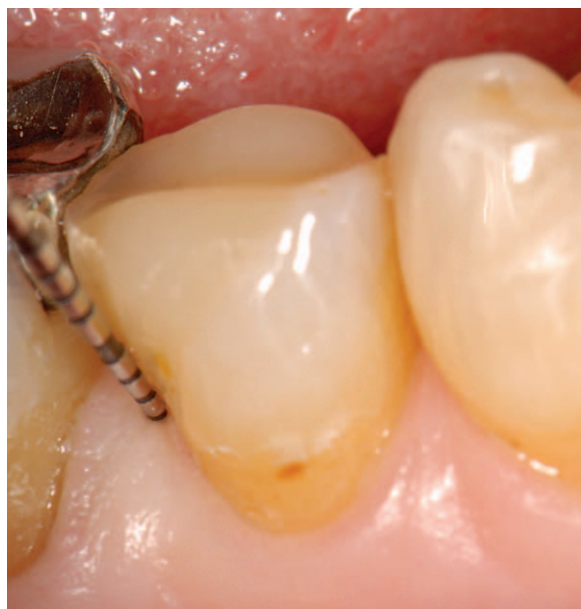

Figure 14. Buccal view after 12 months. The probing pocket depths in the proximal area were 2 mm, and no bleeding occurred on probing.

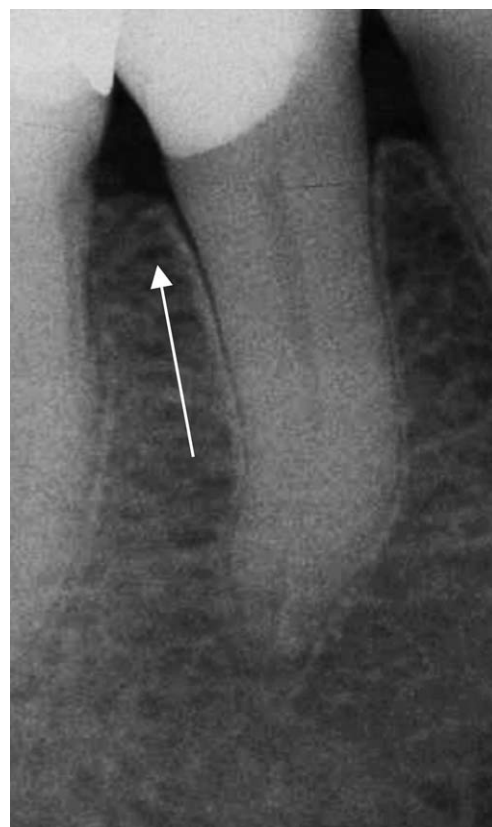

Figure 15. Radiograph of tooth #45 after 12 months. Radiographic examination revealed a distance of 1 mm between the restorative margin and the alveolar crest. Minimal loss of alveolar bone can be observed after 12 months (arrow).

In the clinical case presented, the occluso-proximal restoration margin was located below the CEJ and invaded the biological width. However, no adverse reactions, such as chronic inflammation of soft and hard tissues, attachment loss, or bone resorption, were observed at the 12-month follow-up.

The principle of biological width suggests that severely damaged teeth resulting from trauma or caries should be pretreated surgically or orthodontically to gain an adequate space of supracrestal, sound, hard tissue.<sup>18,19</sup> In contrast to the anatomically defined area of the dentogingival junction, the dimension of the biological width is defined based on several clinical studies and the opinion of experts.<sup>20</sup> Obligatory values do not exist because of individually differing characteristics of gingival morphology, the width of the keratinized gingiva, and periodontal condition.<sup>15</sup>

All radiographs of the presented case were taken using the long-cone parallel technique with Rinn's film holders to achieve utmost accuracy and minimal

distortion.<sup>7</sup> At the 12-month follow-up, the radiographic examination revealed a distance of 0.5–1.0 mm between the restorative margin and the alveolar crest with no signs of clinical inflammation.

### How Can These Clinical Observations Be Explained With the Current Literature?

Restorative margins completely surrounded by sound enamel are an ideal situation for structural conservation of surrounding soft and hard tissues.<sup>21</sup> Extensive and undermining carious lesions or severe trauma often provide the possibility of placing restorative margins in sound enamel. Additionally, the degree of difficulty in placing deep subgingival restorations increases dramatically because of inferior insight into and access to the cavity, leading to problematic marginal control, management of undermining areas, and moisture control.

In a literature review, Brunsvold and Lane<sup>22</sup> could show that the prevalence of marginal overhangs was between 25% and 76% in all restored surfaces. Subgingival restorative margins, and especially marginal overhangs, contribute to plaque accumulation, chronic inflammation, attachment loss, and bone resorption.<sup>20,22</sup> Molars restored with indirect crowns or direct ocluso-proximal restorations showed increased involvement of the furcation compared with sound molars.<sup>23</sup> Furthermore, Flores-de-Jacoby and others<sup>16</sup> reported increased amounts of spirochetes, fusiforms, rods, and filamentous bacteria in subgingival plaque. However, no association was found between restorative margins below the CEJ and the occurrence of secondary caries.<sup>2</sup>

A possible explanation for the sound periodontal and gingival condition in the presented case may be the polished, planed, and nonirritating subgingival margin, which was created during the first step (PBE) of the R2-technique. This, in combination with the distinct oral hygiene protocol, the individually adapted interdental brushes, and their adequate and regular use, may have contributed to the clinical success at the 12-month follow-up.

We assume that during wound healing an epithelial reattachment may have taken place on both the cementum and the apical parts of the composite resin surface. After iatrogenic detachment resulting from surgical or restorative procedures, wound healing takes place, involving hemidesmosomes and the restructuring of the basal

lamina under the influence of fibrin.<sup>24</sup> It is known that epithelial attachment is not specific for one surface structure. It is capable of being formed on enamel, cementum, afibrillar cementum, and cuticle.<sup>24</sup>

### Is Reattachment During Wound Healing on a Plain Resin Composite Surface Possible?

On the basis of our clinical observations, it is not possible to draw any conclusions about epithelial reattachment on a plain resin composite surface. However, a noninflammatory rehabilitation of soft and hard tissue next to deep proximal cavities after PBE can be achieved with the clinical R2-technique presented here.

In restorative dentistry, the search for an ideal material to restore the apical part of deep proximal cavities is not new. Glass ionomer cements,<sup>25,26</sup> polyacid-modified resin composite materials<sup>1,27</sup> and composite resin systems<sup>2</sup> are discussed intensely regarding their role in long-term durability. Yet with increased degree of difficulty, there are some substantial factors influencing the long-term outcome of a restoration substantially below the CEJ. The individual skills of the operator<sup>28</sup> or the degree of contamination with blood or saliva<sup>29</sup> are prone to the development of secondary caries and/or failure of a restoration.

However in recent years, several new techniques, for example the PBE,<sup>5,6</sup> the elastic cavity wall,<sup>3,4</sup> and the Snowplough technique<sup>17</sup> (Figure 6) were developed to increase clinical success in managing difficult situations. They provide promising approaches to manage complex direct resin restorations on severely decayed teeth. Remarkably, these techniques are mainly designated for building up only parts of teeth, here proximal areas. It is assumed that the violation of the biological width within a limited extent, under the precondition of superior oral hygiene, can be successful. Further experimental and clinical research should be encouraged to gain further information on relevant questions, such as the tolerable extent of violation of the biological width, favorable materials in the subgingival area and their long-term bond strength and surface characteristics, and the evaluation of patient characteristics.

## CONCLUSION

### Advantages

1. The two-step R2-technique (step one: PBE; step two: direct composite resin restoration) provides



an additional treatment option for the restoration of deep and undermining cavities reaching below the CEJ.

2. Distinct oral hygiene training (including the use of accurately fitting interdental brushes) in patients with occluso-proximal restorations invading the biological width is necessary to achieve a noninflammatory clinical situation.
3. It is assumed that the extent of biological width violation plays a role in the biological reaction of soft and hard tissues: limited proximal area versus complete circumferential margin.

### Disadvantages

1. The type of restoration, materials used, and marginal quality are determining factors in the clinical performance of restorations invading the biological width (direct versus indirect restorations).
2. The reasons for individual variations in biological response to restorations below the CEJ that are invading biological width are yet unknown.
3. There is no evidence in the literature about the long-term bond strength and marginal quality of two-step composite resin restorations.

### Conflict of Interest

The authors of this manuscript certify that they have no proprietary, financial, or other personal interest of any nature or kind in any product, service, and/or company that is presented in this article.

(Accepted 26 March 2013)

### References

1. Dietrich T, Kraemer M, Losche GM, & Roulet J (2000) Marginal integrity of large compomer Class II restorations with cervical margins in dentine *Journal of Dentistry* **28**(6) 399-405.
2. Kuper NK, Opdam NJ, Bronkhorst EM, & Huysmans MC (2012) The influence of approximal restoration extension on the development of secondary caries *Journal of Dentistry* **40**(3) 241-247.
3. Cavalcanti AN, Mitsui FH, Ambrosano GM, & Marchi GM (2007) Influence of adhesive systems and flowable composite lining on bond strength of Class II restorations submitted to thermal and mechanical stresses *Journal of Biomedical Materials Research. Part B, Applied biomaterials* **80**(1) 52-58.
4. Stefanski S, & van Dijken JW (2012) Clinical performance of a nanofilled resin composite with and without an intermediary layer of flowable composite: A 2-year evaluation *Clinical Oral Investigations* **16**(1) 147-153.
5. Frankenberger R, Hehn J, Hajto J, Kramer N, Naumann M, Koch A, & Roggendorf MJ (2013) Effect of proximal box elevation with resin composite on marginal quality of ceramic inlays in vitro *Clinical Oral Investigations* **17**(1) 177-183.
6. Roggendorf MJ, Kramer N, Dippold C, Vosen VE, Naumann M, Jablonski-Momeni A, & Frankenberger R (2012) Effect of proximal box elevation with resin composite on marginal quality of resin composite inlays in vitro *Journal of Dentistry* **40**(12) 1068-1073.
7. Dibart S, Capri D, Kachouh I, Van Dyke T, & Nunn ME (2003) Crown lengthening in mandibular molars: A 5-year retrospective radiographic analysis *Journal of Periodontology* **74**(6) 815-821.
8. Gargiulo A, Wentz FM, & Orban B (1961) Dimensions and relations of the dentogingival junction in humans *Journal of Periodontology* **32**(3) 261-267.
9. Vacek JS, Gher ME, Assad DA, Richardson AC, & Giambarrresi LI (1994) The dimensions of the human dentogingival junction *International Journal of Periodontics & Restorative Dentistry* **14**(2) 154-165.
10. Ingber JS, Rose LF, & Coslet JG (1977) The "biologic width"—A concept in periodontics and restorative dentistry *Alpha Omegan* **70**(3) 62-65.
11. Nevins M, & Skurow HM (1984) The intracrevicular restorative margin, the biologic width, and the maintenance of the gingival margin *International Journal of Periodontics & Restorative Dentistry* **4**(3) 30-49.
12. Gunay H, Seeger A, Tschernitschek H, & Geurtsen W (2000) Placement of the preparation line and periodontal health—A prospective 2-year clinical study *International Journal of Periodontics & Restorative Dentistry* **20**(2) 171-181.
13. Lanning SK, Waldrop TC, Gunsolley JC, & Maynard JG (2003) Surgical crown lengthening: Evaluation of the biological width *Journal of Periodontology* **74**(4) 468-474.
14. Newcomb GM (1974) The relationship between the location of subgingival crown margins and gingival inflammation *Journal of Periodontology* **45**(3) 151-154.
15. Maynard JG Jr, & Wilson RD (1979) Physiologic dimensions of the periodontium significant to the restorative dentist *Journal of Periodontology* **50**(4) 170-174.
16. Flores-de-Jacoby L, Zafiropoulos GG, & Ciancio S (1989) Effect of crown margin location on plaque and periodontal health *International Journal of Periodontics & Restorative Dentistry* **9**(3) 197-205.
17. Opdam NJ, Roeters JJ, de Boer T, Pesschier D, & Bronkhorst E (2003) Voids and porosities in Class I micropreparations filled with various resin composites *Operative Dentistry* **28**(1) 9-14.
18. Hempton TJ, & Dominici JT (2010) Contemporary crown-lengthening therapy: A review *Journal of the American Dental Association* **141**(6) 647-655.
19. Krastl G, Filippi A, Zitzmann NU, Walter C, & Weiger R (2011) Current aspects of restoring traumatically fractured teeth *European Journal of Esthetic Dentistry: Official Journal of the European Academy of Esthetic Dentistry* **6**(2) 124-141.
20. Padbury A Jr, Eber R, & Wang HL (2003) Interactions between the gingiva and the margin of restorations *Journal of Clinical Periodontology* **30**(5) 379-385.

21. Silness J (1980) Fixed prosthodontics and periodontal health *Dental Clinics of North America* **24(2)** 317-329.
22. Brunsvold MA, & Lane JJ (1990) The prevalence of overhanging dental restorations and their relationship to periodontal disease *Journal of Clinical Periodontology* **17(2)** 67-72.
23. Wang HL, Burgett FG, & Shyr Y (1993) The relationship between restoration and furcation involvement on molar teeth *Journal of Periodontology* **64(4)** 302-305.
24. Stern IB (1981) Current concepts of the dentogingival junction: The epithelial and connective tissue attachments to the tooth *Journal of Periodontology* **52(9)** 465-476.
25. Dietrich T, Losche AC, Losche GM, & Roulet JF (1999) Marginal adaptation of direct composite and sandwich restorations in Class II cavities with cervical margins in dentine *Journal of Dentistry* **27(2)** 119-128.
26. Francisconi LF, Scaffa PM, de Barros VR, Coutinho M, & Francisconi PA (2009) Glass ionomer cements and their role in the restoration of non-carious cervical lesions *Journal of Applied Oral Science: Revista FOB* **17(5)** 364-369.
27. Lindberg A, van Dijken JW, & Lindberg M (2007) Nine-year evaluation of a polyacid-modified resin composite/resin composite open sandwich technique in Class II cavities *Journal of Dentistry* **35(2)** 124-129.
28. Frankenberger R, Reinelt C, Petschelt A, & Kramer N (2009) Operator vs. material influence on clinical outcome of bonded ceramic inlays *Dental Materials: Official Publication of the Academy of Dental Materials* **25(8)** 960-968.
29. Dietrich T, Kraemer M, Losche GM, Wernecke KD, & Roulet JF (2000) Influence of dentin conditioning and contamination on the marginal integrity of sandwich Class II restorations *Operative Dentistry* **25(5)** 401-410.