

Influence of Application Techniques on Contact Formation and Voids in Anterior Resin Composite Restorations

SR Kwon • U Oyoyo • Y Li

Clinical Relevance

Diastema closure with direct resin composites should be free of voids and establish proper contact formation. Good results can be achieved with the pull-through technique and the use of prefabricated matrices.

SUMMARY

This study evaluated the influence of three different application techniques on contact formation and voids in anterior resin composite restorations. Artificial ivory teeth were randomly assigned to three experimental groups, with 20 specimens in each group. One operator performed all restorations using the Teflon tape, pull-through, or bioclear matrix technique. The treatment time required for each restoration was recorded. An examiner blinded to the treatment group performed the visual evaluation of six crite-

ria, including proper contact formation. The restored teeth were cut to yield a total of 180 sections for microscopic evaluation. The Kruskal-Wallis procedure was performed to evaluate the significance of treatment time, number of voids, percent porosity area, and void diameter. There were significant differences in treatment time among the three groups ($p < 0.05$). The bioclear matrix technique required the least time for the treatment of one diastema closure ($p < 0.05$). The Teflon tape technique resulted in proper contact formation in 80% of specimens, a rate that was significantly lower than that associated with the pull-through and bioclear matrix techniques ($p < 0.05$). Out of 540 imaging areas 160 images were free of voids. The number of voids and the percent porosity area were not significantly different among the three techniques ($p > 0.05$). However, the mean void diameter was greater with the bioclear matrix technique compared to the other two techniques ($p < 0.05$).

*So Ran Kwon, DDS, MS, PhD, MS, Department of Operative Dentistry, University of Iowa College of Dentistry, Iowa City, IA, USA

Udochukwu Oyoyo, MPH, Loma Linda University, School of Dentistry, Dental Education Services, Loma Linda, CA, USA

Yiming Li, DDS, MSD, PhD, Loma Linda University, School of Dentistry, Loma Linda, CA, USA

*Corresponding author: 801 Newton Road, Iowa City, IA 52246, USA; e-mail: soran-kwon@uiowa.edu

DOI: 10.2341/13-060-L

INTRODUCTION

Diastema closure with direct resin composite restorations can be a conservative treatment modality to improve the appearance of a smile. Direct resin composite bonding may lack the permanence of indirect veneers and full coverage restorations. However, conservation of sound tooth structure, shorter treatment time, ease of repair, and the low cost of the treatment compared to other treatment modalities are distinct advantages of direct bonding.¹

Diastema closures in the anterior dentition can be accomplished without the use of a matrix or wedge, thus providing better control of proximal contours in the gingival embrasure areas.² In these cases, a Teflon tape is commonly used to prevent bonding to the adjacent tooth. A tight and properly contoured contact can also be achieved using a “pull-through” matrix technique, whereby a strip is pulled from the facial toward the lingual to push the resin material through the proximal to form a smooth contour adapted properly to the adjacent tooth.^{1,3} Another approach is to use custom fabricated matrices with a combination of flowable composite and a syringeable composite filling technique.⁴

Success with resin composite restorations requires a disciplined technique, and the restorative dentist seems to have the greatest effect on longevity.⁵ Proper contact formation and margin adaptation may be considered as critical steps in the treatment of space closure using direct resin composite restorations. The use of a proper application technique should ideally establish a tight contact and a restoration free of voids and porosities.

The influence of various application procedures on cavity wall adaptation and void formation has been investigated on posterior Class I and Class II cavities.⁶⁻⁹ This is an important issue since many studies consider the presence of voids and porosities to be disadvantageous to the restoration. First, voids compound the problem of producing a smooth surface to a composite restoration.¹⁰ Second, voids result in a lower resistance to fatigue that may influence durability.¹¹ Third, flaws introduced during the clinical handling of resin composites will have a negative effect on the flexural strength of the material.¹² Fourth, increased void content leads to an increase in polymerization shrinkage, predisposing restorations to marginal leakage, staining, and secondary caries.¹³

The injection of a syringeable composite has been reported^{7,8} to result in a better restoration with less

voids compared to a packing technique with a highly viscous composite in posterior Class I restorations. The use of uncured flowable composite with a layer of medium-viscous composite injected—referred to as the “snow-plough technique”—produced the most homogeneous restoration in small posterior cavities.⁹ However, there is a lack of information on the comparison of different application techniques with regard to the formation of voids in anterior restorations. Thus, the purpose of this study was to evaluate the influence of three different application techniques on the contact formation and voids in anterior resin composite restorations on simulated diastemas in artificial ivory teeth. The null hypotheses to be tested were that there would be no differences among the three techniques in 1) the treatment time required, 2) establishment of proper contact and contour, and 3) void formation within the resin composite restorations.

MATERIALS AND METHODS

Specimen Preparation

Sixty artificial ivory teeth (#9) were marked with a pencil to enable standardization of a 1.5-mm mesial diastema when trimmed with a model trimmer (Orthodontic model trimmer, Whip MixAE, Louisville, KY, USA). In order to facilitate bonding, air-polishing (Prophy-Jet, Dentsply, York, PA, USA) was performed on the trimmed surface. The teeth were randomly assigned to three experimental groups, with 20 specimens in each group, and mounted on a phantom-head dentoform (Columbia Dentoform Corp, Long Island, NY, USA).

Application Techniques

Table 1 summarizes the step-by-step procedure for the three different application techniques, and Table 2 summarizes the restorative materials used.

Group A (Teflon Tape Technique)—The adjacent tooth (#8) was wrapped around with a Teflon tape (Teflon plumbers tape, Westbrass, Los Angeles, CA, USA) to prevent inadvertent bonding. A one-component, self-etching, light-cured dental adhesive (Bond Force Kit, Tokuyama Corporation, Tokyo, Japan) was applied and rubbed onto the surface (20 seconds) and light-cured (20 seconds). A syringeable composite (Estelite Omega PLT, Tokuyama Corporation) was injected from the labial and the lingual and sculpted with a composite placement instrument (Gold Microfil, Almore International Inc, Portland, OR, USA), followed by light-curing for 40 seconds with an LED light-curing unit (Valo-light: 1717 mW/

Table 1: *Step-by-Step Protocol by Application Technique*

Group	Step-by-Step Protocol
A: Teflon tape technique	1. Teflon tape is placed around #8
	2. Resin adhesive is applied on #9 and light-cured (LC)
	3. Resin composite is placed on #9, sculpted, and LC
	4. Teflon tape is removed from #8
	5. Gingival margin is shaped with #12 scalpel blade
	6. Restoration is finished and polished
B: Pull-through technique	1. Resin adhesive is applied on #9 and LC
	2. Celluloid strip is placed and resin composite applied on #9 and sculpted
	3. Strip is pulled from lingual to facial, composite contoured with brush, and LC
	4. Celluloid strip is placed and resin composite applied and sculpted
	5. Strip is pulled from facial to lingual, composite contoured with brush, and LC
	6. Restoration is finished and polished
C: Bioclear matrix technique	1. Bioclear diastema closure matrix is placed mesially to #9
	2. Resin adhesive is applied on #9 but not LC
	3. Flowable composite is injected into the cervical area and then LC
	4. Tooth separation is created with a wedge
	5. Adhesive resin, flowable composite, and paste composite are placed and LC
	6. Bioclear diastema closure matrix is removed
	7. Restoration is finished and polished

cm²; Ultradent Products Inc, South Jordan, UT, USA). The restoration was finished with contouring discs (Soflex kit, 3M, St Paul, MN, USA) and strips (Epitex strips, GC America Inc, Alsip, IL, USA).

Group B (Pull-Through Technique)—On application of the syringeable composite, the bulk of composite was first pulled from the lingual to the facial with a celluloid strip (Celluloid strip, GC America Inc). After sculpting and light-curing the procedure was repeated from the facial toward the lingual. The restoration was sculpted, light-cured, and finished.

Group C (Bioclear Matrix Technique)—A prefabricated matrix (Bioclear diastema closure matrix,

Bioclear, Tacoma, WA, USA) was stabilized into the gingival area. A flowable composite (Estelite Flow Quick, Tokuyama Corporation) was injected into the cervical area and light-cured. Tooth separation was performed with a wedge (G-Wedge, Garrison Dental Solutions, Spring Lake, MI, USA). A small amount of flowable resin was injected followed by a syringeable composite to fill the matrix and the restoration was light-cured. The matrix was gently removed and the restoration finished.

One operator with 20 years of clinical experience performed all 60 restorations. The application and finishing time required for each restoration were recorded.

Visual Evaluation of Contact Areas, Embrasures, and Line Angles

The evaluation criteria for proper formation of contact areas, embrasures, and line angles are summarized in Table 3. An examiner blinded to the treatment group performed the evaluation of the six criteria with a dental loupe (2.5× magnification). Each criterion was determined to be either correct or an error, with one point given to a correct criterion.

Microscopic Evaluation of Porosity Formation

On completion of the visual evaluation tooth #9 was removed from the model and mounted on a sectioning machine (TechCut 4, Allied High Tech Products Inc, Compton, CA, USA) to prepare three 0.5-mm sections representative of the incisal, middle, and gingival areas. Figure 1 illustrates the location of the sections relative to the incisal edge and the labial cervical line. The sections were sequentially polished with special silicon carbide grinding papers (Micro-cut, grit 400, 600, and 1200; Buehler, Lake Bluff, IL, USA) to a thickness of approximately 200 µm.

A total of 180 polished sections were viewed under the microscope at 20× magnification (Olympus BH2, Olympus Corporation, Tokyo, Japan), and images were taken at three different areas per section. Figure 2 illustrates the imaging location. Each area was measured for number of voids, void diameter, total viewing area, and total porosity area with image J analysis software (National Institutes of

Table 2: *Restorative Materials Used in this Study*

Material	Manufacturer	Mean Filler Size, nm	Filler Content, vol%	Color	Lot No.
Bond Force Kit	Tokuyama Corporation, Tokyo, Japan	—	—	—	108EY2
Estelite Flow Quick	Tokuyama Corporation, Tokyo, Japan	300	53	A1	070EY2
Estelite Omega PLT	Tokuyama Corporation, Tokyo, Japan	200	71	EA1	006E41

Table 3: Evaluation Criteria for Contact Area, Embrasures, and Line Angles		
Criteria	Correct	Error
Mesial contact	Visual contact, correct width and position, tight	Wide narrow, too incisal, too gingival, too facial, too lingual, irregular, loose
MF embrasure	Normal contour following adjacent tooth	Closed, open, irregular
MF line angle	Correct shape and position	Too straight, too angled, too sharp, too round
MG embrasure	Normal contour following adjacent tooth	Closed, open, irregular
MI embrasure	Normal contour following adjacent tooth	Closed, open, irregular
ML embrasure	Normal contour following adjacent tooth	Closed, open, irregular
MF: mesio-facial; MG: mesio-lingual; MI: mesio-incisal; ML: mesio-lingual		

Health, Bethesda, MD, USA) (Figure 3). The percent area of porosity was calculated with the following equation:

Percentage (%) porosity = total porosity area/
total viewing area × 100.

As a control procedure five preloaded composite tips and one flowable composite syringe were evaluated for porosities. Five millimeters of the tip was removed with a blade and the composite inside was light-cured for 60 seconds. The cured composite was removed from the tip or the syringe, sectioned, and polished to prepare three 200-μm-thick sections for microscopic evaluation.

Statistical Analysis

The nonparametric Kruskal-Wallis procedure with Bonferroni pairwise post hoc comparisons was performed to evaluate the distribution of the total treatment time, number of voids, percent porosity area, and mean void diameter. Chi-square tests were used to compare the proportion of samples demonstrating contact among the three techniques. All tests of significance were two-sided and were conducted at an alpha level of 0.05 with SAS v 9.1.3 (SAS Institute, Cary, NC, USA).

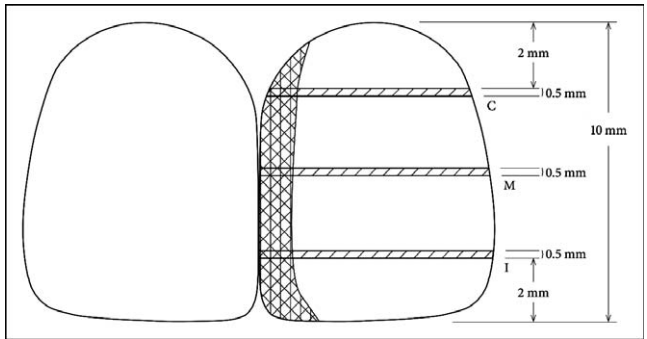


Figure 1. Design of diastema closure and sectioning of tooth.

RESULTS

Treatment Time

Kruskal-Wallis test followed by pairwise comparisons showed significant differences in application, finishing, and total treatment times among the three groups ($p<0.05$) (Table 4). The bioclear matrix technique required the least time for the treatment of one diastema closure ($p<0.05$).

Visual Evaluation of Contact Formation

The Teflon tape technique demonstrated contact formation in 80% of specimens, which was significantly lower than in 100% of the pull-through and bioclear matrix technique specimens ($p<0.05$) (Table 5). The embrasure and line angle criteria produced almost no errors with all three techniques so no statistical analysis was performed.

Evaluation of Porosity Formation by Technique

Microscopic evaluation of the composite sections taken from five preloaded tips and one flowable composite syringe showed that the materials were free of porosities. The voids in the restorations were spherical in shape and occurred mainly along the

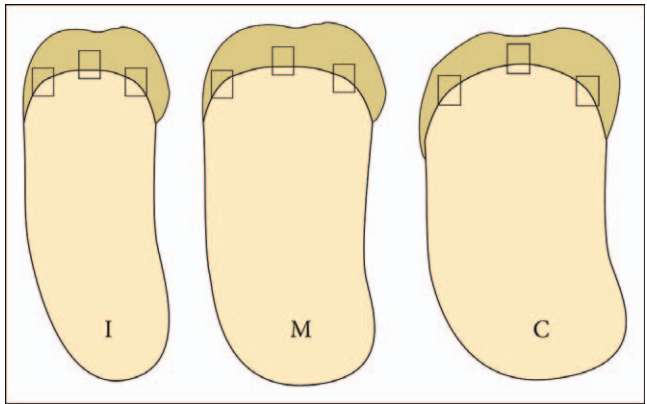


Figure 2. Imaging areas on sections.

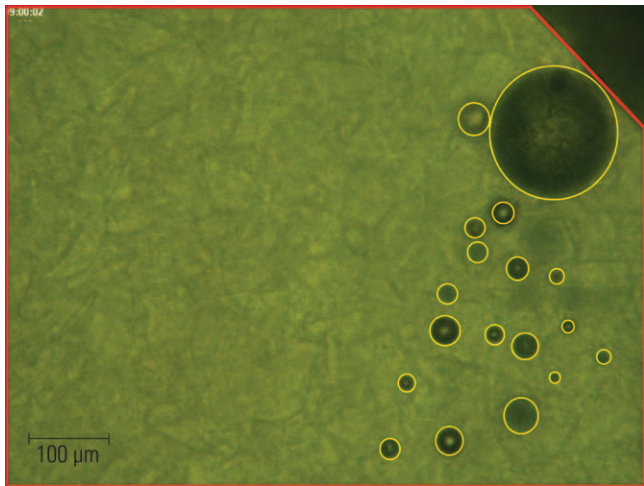


Figure 3. Calculation of total viewing area (red) and total porosity area (yellow) with Image J software.

artificial tooth and adhesive/resin composite interface (Figure 4).

Out of 540 imaging areas 160 images were free of voids. The number of voids and the percent porosity area were not significantly different among the three techniques ($p>0.05$). However, the mean void diameter was greater with the bioclear matrix technique compared to the Teflon tape and pull-through techniques ($p<0.05$). The mean values and standard deviations (SDs) of porosity data by technique and location are summarized in Table 6 and illustrated as box plots in Figures 5 through 7.

DISCUSSION

This phantom-head dentoform setup in a clinical laboratory reflects the porosities related to different techniques under ideal circumstances and indicates that the clinical handling with challenges of the oral environment may result in different, less favorable results.

The composites selected for this study were shown to be free of porosities when cured from within the syringe or tip. This finding is in accordance with

Table 4: Application, Finishing, and Total Treatment Time Values [Mean (standard deviation [SD])] in Minutes, by Technique ^a			
	A: Teflon Tape	B: Pull-Through	C: Bioclear Matrix
Application time	8.9 (1.7) A	12.5 (1.7) B	6.1 (1.2) C
Finishing time	4.8 (0.6) A	2.3 (0.4) B	5.3 (0.7) A
Total treatment time	13.6 (1.8) A	14.7 (1.7) A	11.4 (1.3) B
^a Within a row, same letters indicate means that are not statistically different ($p>0.05$).			

Table 5: Frequency of Contact Formation by Technique ^a				
	Technique			Total
	A: Teflon Tape	B: Pull-Through	C: Bioclear Matrix	
No contact	4	0	0	4
Contact	16	20	20	56
Total	20	20	20	60
^a Pearson chi-square = 8.571 (df=2), $p = 0.014$.				

those of the study of Opdam and others,⁸ in which the unused tip of a composite was used as the control. However, other studies^{10,14,15} in which the composite material was extruded from the syringe showed microporosities. The authors of these studies stated that voids are mainly introduced as the material is extruded through the orifice of the syringe.

This study measured the number of voids, percent porosity area, and the void diameter. The mean number of voids and the mean percent porosity area ($\approx 1.0\%$) were relatively small so that homogeneous restorations could be achieved with all three techniques used.

Clinically, the void diameter can be considered most important, since large voids may lead to a lower resistance to fatigue and decreased wear resistance.⁸ Interestingly, there was no difference among the three techniques in terms of the number of voids and the percent porosity area, whereas the bioclear matrix technique exhibited significantly larger voids in diameter. One explanation for this difference may be the use of a combination of flowable and syringeable composite in the middle area that may be more prone to air entrapment, resulting in the




Figure 4. Voids along tooth and adhesive/restoration interface.

Table 6: Number of Voids, Percent Porosity Area, and Void Diameter [Mean (standard deviation [SD])] by Technique and Location ^a				
	Location	A: Teflon Tape	B: Pull-Through	C: Bioclear Matrix
Number of voids	Incisal	2.22 (3.64)	2.40 (2.90) A	2.65 (2.58) A
	Middle	2.62 (3.04) a	4.27 (4.82) bB	4.22 (3.39) bB
	Cervical	2.67 (2.61)	2.58 (2.08) A	1.88 (2.57) A
	Total	2.50 (3.12)	3.08 (3.55)	2.92 (3.02)
Percent porosity area	Incisal	0.94 (1.54)	0.86 (1.15)	1.10 (1.27) A
	Middle	1.02 (1.16) ab	0.92 (1.11) a	1.49 (1.38) bA
	Cervical	0.95 (1.11)	1.14 (2.00)	0.70 (1.12) B
	Total	0.97 (1.28)	0.97 (1.47)	1.10 (1.29)
Void diameter, µm	Incisal	26.58 (33.46) a	26.96 (28.20) a	37.91 (33.46) bA
	Middle	31.95 (25.07) a	26.63 (23.19) a	43.40 (31.20) bA
	Cervical	30.10 (27.85)	31.73 (27.22)	25.56 (32.06) B
	Total	29.54 (28.93) a	28.43 (26.25) a	36.62 (32.93) b

^a Within rows, different lowercase letters indicate means that are statistically different ($p<0.05$); within columns, different uppercase letters indicate means that are statistically different by location ($p<0.05$).

formation of larger voids with the bioclear matrix technique. This explanation is contrary to the results in occlusal preparations, in which the use of the “snow-plough technique” produced the most homogeneous restoration.⁹ This discrepancy might be explained by the ability to apply pressure and by the better access to Class I cavities, whereas there is only limited access of the syringe in the anterior region, limited partly by the prefabricated matrix.

The use of a small amount of composite rolled into the shape of a ball and subsequently applied with a composite applicator may facilitate access and

reduce the void diameter when using the bioclear matrix technique.

Opdam and others⁷ showed differences in porosity within the composite by the type of operator. The dental student operator produced the best results. The authors speculated that this was due to the fact that students are more likely than general practitioners to follow the protocol. In our study, one operator performed all of the restorations, which also explains the relatively small SDs in treatment time and percent porosity area. Further studies should be performed to evaluate which technique is more

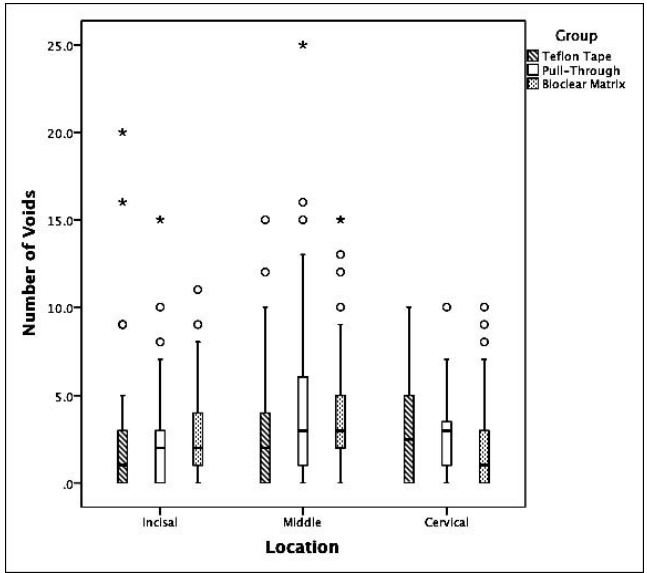


Figure 5. Box plots of number of voids by technique and location (o, outliers; *, extreme data points).

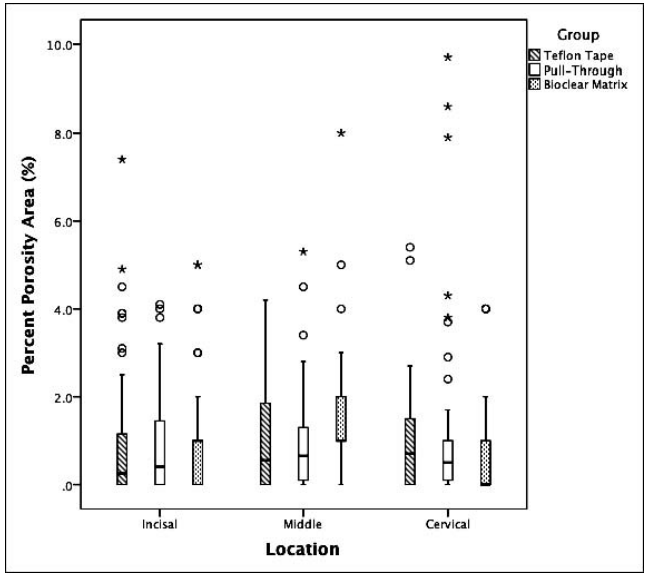


Figure 6. Box plots of percent porosity area by technique and location (o, outliers; *, extreme data points).

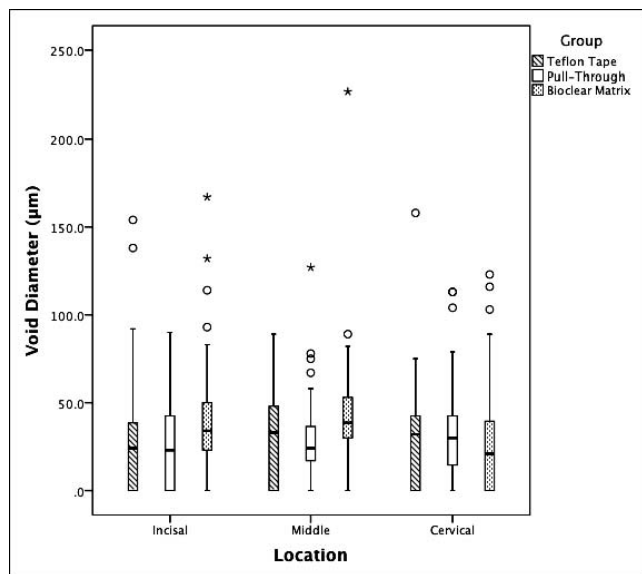


Figure 7. Box plots of void diameter by technique and location (o, outliers; *, extreme data points).

easily learned and applied by operator type. Future studies may also include different types of application techniques that have not been addressed in this study.

Proper contact formation is essential for the esthetics and function of a diastema closure. The frequency of contact formation was less with the Teflon tape technique compared to the other techniques. We suggest pre-wedging to improve the outcome with the Teflon tape technique. The dentofrom setup is limited in simulating the elasticity of periodontal ligaments *in vivo*. However, the artificial gingiva and minute movement of artificial teeth in the socket enable the use of pre-wedging.

Based on the results, the treatment time for a single diastema closure was significantly smaller using a prefabricated matrix, leading to the rejection of our first null hypothesis. The second null hypothesis was rejected, since the pull-through and bioclear matrix techniques provided better contact than did the Teflon tape technique. The third null hypothesis was partly rejected, as the void diameter in the composite restoration was larger in the bioclear matrix group compared to the other two technique groups.

CONCLUSIONS

Diastema closure with direct resin composites should be void-free and should establish proper contact formation. The results of this study showed that void-free restorations were difficult to obtain.

However, all application techniques used produced relatively homogeneous restorations. The best results in contact formation could be achieved with the pull-through and bioclear matrix techniques.

Acknowledgements

We would like to thank Tokuyama Dental America Inc for kindly providing all restorative materials used in this study.

Conflict of Interest

The authors of this manuscript certify that they have no proprietary, financial, or other personal interest of any nature or kind in any product, service, and/or company that is presented in this article.

(Accepted 5 March 2013)

REFERENCES

1. Kwon SR, & Denehy GE (2011) Predictable diastema closure using an innovative, indirect mock-up technique *Cosmetic Dentistry* **5**(3) 12-15.
2. Murchison DF, Roeters J, Vargas MA, & Chan DCN (2006) Direct anterior restorations In: Summitt JB, Robbins JW, Hilton TJ, Schwartz RS (eds) *Fundamentals of Operative Dentistry* Quintessence, Chicago 273-277.
3. Denehy GE (2000) A direct approach to restore anterior teeth *American Journal of Dentistry* **13**(Special Issue) 55D-59D.
4. Clark DJ (2008) Restoratively driven papilla regeneration: Correcting the dreaded "black triangle" *Canadian Journal of Restorative Dentistry and Prosthodontics* **8** 21-27.
5. Denehy GE (2009) Composite resins *Compendium of Continuing Education in Dentistry* **30**(6) 366-367.
6. Chuang SF, Liu JK, Chao CC, Liao FP, & Chen YHM (2012) Effects of flowable and composite lining and operator experience on microleakage and internal voids in Class II composite restorations *Journal of Prosthetic Dentistry* **85**(2) 177-183.
7. Opdam NJM, Roeters JJM, Joosten M, & vd Veeke O (2002) Porosities and voids in Class I restorations placed by six operators using a packable or syringable composite *Dental Materials* **18**(1) 58-63.
8. Opdam NJM, Roeters JJM, Peters TCRB, Burgersdijk RCW, & Teunis M (1996) Cavity wall adaptation and voids in adhesive Class I resin composite restorations *Dental Materials* **12**(7) 230-235.
9. Opdam NJM, Roeters JJM, Pesschier TBD, & Bronkhorst E (2003) Voids and porosities in Class I micropreparations filled with various resin composites *Operative Dentistry* **28**(1) 9-14.
10. Ogden AR (1985) Porosity in composite resins—An Achilles' heel? *Journal of Dentistry* **13**(4) 331-334.
11. McCabe JF, & Ogden AR (1987) The relationship between porosity, compressive fatigue limit and wear in the resin

- composite restorative materials *Dental Materials* **3**(1) 9-12.
12. Huysmans MCDNJM, Varst PGT, Lautenschlager EP, & Monaghan P (1996) The influence of simulated clinical handling of the flexural and compressive strength of posterior composite restorative materials *Dental Materials* **12**(3) 116-120.
13. Goldman M (1983) Polymerization shrinkage of resin based restorative materials *Australian Dental Journal* **28**(3) 156.
14. Fano V, Ortalli I, & Pozela K (1995) Porosity in composite resins *Biomaterials* **16**(17) 1291-1295.
15. Jørgensen KD, & Hisamitsu H (1983) Porosity in microfill restorative composites cured by visible light *Scandinavian Journal of Dental Research* **91**(5) 396-405.