

Use of a Modified Matrix Band Technique to Restore Subgingival Root Caries

MG Brackett • JM Ryan • FJ Haddock • MF Romero • WW Brackett

Clinical Relevance

A modified matrix technique used in combination with an RMGI restorative material is an effective approach for treating subgingival root caries.

SUMMARY

Given the increasing incidence of root caries in the elderly population, clinicians frequently must isolate and restore subgingival preparations. This article demonstrates a technique utilizing a modified Tofflemire matrix band that creates a preparation free of crevicular fluid and blood for restoration with resin-modified glass ionomer cement.

INTRODUCTION

Root caries have become one of the most significant patient management problems in the elderly popu-

*Martha G Brackett, DDS, MSD, Restorative Sciences, Augusta University Dental College of Georgia, Augusta, GA, USA

Jennifer M Ryan, BS, Restorative Sciences, Augusta University Dental College of Georgia, Augusta, GA, USA

Fernando J Haddock, DDS, Restorative Sciences, Augusta University, Augusta, GA, USA

Mario F Romero, DDS, Restorative Sciences, Augusta University, Augusta, GA, USA

William W Brackett, DDS, MSD, Restorative Sciences, Augusta University, Augusta, GA, USA

*Corresponding author: Augusta University Dental College of Georgia, 1120 15th St, Augusta, Georgia 30912, USA; e-mail: mbrackett@augusta.edu

DOI: 10.2341/17-142-T

lation because these patients frequently exhibit xerostomia, often medication induced, which increases the incidence of root caries.¹

Given the lack of enamel in cervical areas, resin-modified glass ionomer (RMGI) materials are an ideal choice for such restorations.²⁻⁴ A recent systematic review found that RMGI restorations bond more effectively and durably in root surface restorations than do other adhesive materials,⁵ while other studies demonstrate reasonable success in patients with xerostomia.^{6,7} Unfortunately, RMGI restorative materials are difficult to sculpt when used for large restorations, which can result in extensive finishing being necessary. Further, cervical caries that extend subgingivally are particularly challenging to isolate because the tissue is usually inflamed and bleeds easily. This must be controlled to adequately place any adhesive restoration.⁸

Rubber dam isolation using a 212 clamp, placement of retraction cord, and minor periodontal surgery are effective adjuncts in achieving access in subgingival restorations,⁹ but these can be complex and time consuming. Often, use of a customized matrix band offers a simpler approach to attaining isolation and minimizing finishing of RMGI restorations. Manufacturers produce a variety of prefabricated matrix shapes for this purpose, but these must be added to practice inventory. Modification of a matrix band already in inventory is

simpler, and several authors have suggested the use of a modified Mylar strip for cervical RMGI restorations.^{10,11} We favor a modified metal matrix band, which can be readily contoured.

The purpose of this clinical technique article is to present a simple modification of a metal matrix band that greatly facilitates isolation and minimizes the finishing needed for subgingival Class V restorations with RMGI materials.

CLINICAL CASE

Patient Description

A 60-year-old Caucasian male presented to the student clinic at the Dental College of Georgia, Augusta University, seeking comprehensive dental treatment. On review of his medical history, he was classified as ASA III (severe systematic controlled disease) due to diabetes, hypertension, and history of heart attack. The clinical exam revealed the following: all mandibular molars and teeth numbers 5 and 6 missing, generalized moderate-to-severe chronic periodontitis, generalized recession, gingival inflammation and bleeding, occlusion only on posterior teeth with an irregular occlusal plane. At the time of the exam, his caries risk was high because of multiple carious lesions, many missing and restored teeth, as well as fair oral hygiene and xerostomia due to medications (Figure 1).

Caries Management

The patient underwent scaling and root planning and was scheduled for extractions. It was recommended that he decrease the frequency with which he ingested carbohydrates and use a 5000 ppm NaF toothpaste and xylitol gum. Root caries were restored with RMGI restorations.

Treatment of Left Maxillary Lateral Incisor

The tooth shade was determined to be A3. Anesthesia was attained by infiltration with lidocaine HCl 2% with epinephrine 1:100,000 (Xylocaine, Septodont, Lancaster, PA, USA). Isolation was done with cotton rolls. Ultrapack retraction cord #00 (Ultradent Products, Inc, South Jordan, UT, USA) was placed in the facial gingival sulcus during cavity preparation because the lesion was at the level of the gingiva. Cavity preparation was initiated with a No. 2 carbide bur (SS White, Lakewood, NJ, USA) using a high-speed handpiece under constant water cooling, and caries removal was completed with a No. 6 latch-type carbide bur at slow speed (Figure 2).

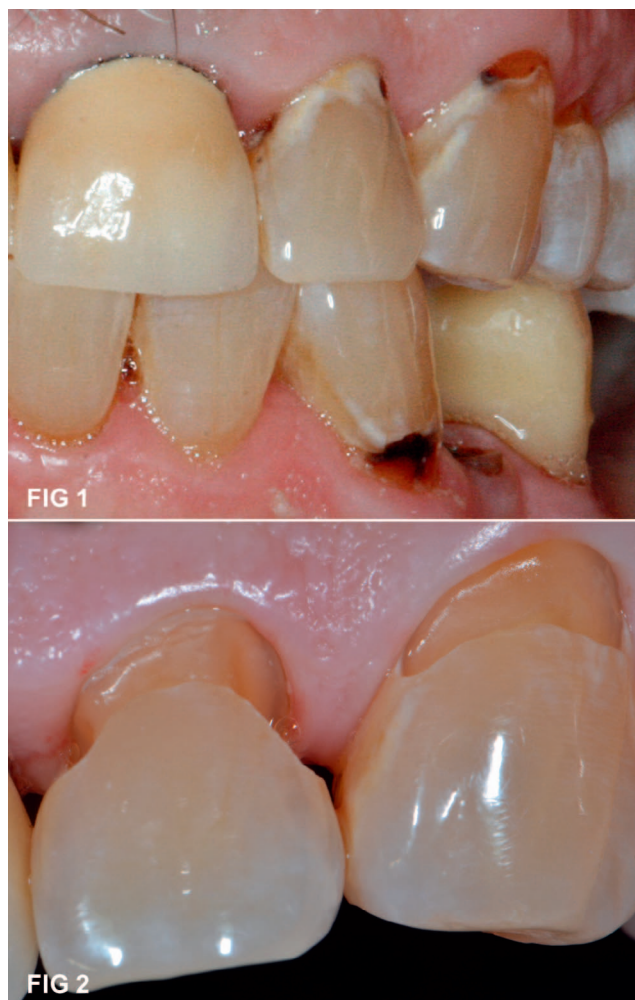

Figure 1. Initial root caries.

Figure 2. Root caries prepared.

Modified Matrix Technique

To form the custom matrix for this restoration, the center of the occlusal side of a universal Tofflemire No. 1 matrix band (JR Rand Corp, Deer Park, NY, USA) (Figure 3a, arrow) was trimmed with fixed-curve crown scissors to a width of 3 mm using a curvature opposite that of the band on that side. The two ends of the matrix band were then trimmed by 1.5 cm each (Figure 3b). The modified matrix was then molded using finger pressure to form the convex, arch-shaped facial contour of the tooth. The trimmed occlusal portion of the modified band became the gingival side of the custom matrix (Figures 4 and 5, arrow). Before placing the matrix, the retraction cord was removed. The modified matrix was then placed around the prepared tooth and into the gingival sulcus where necessary. Two small Wizard wooden wedges (Prestige Dental Products, Inc, Anaheim, CA, USA) were placed on




Figure 3. Universal Tofflemire band. a. Arrow indicates the occlusal portion and area to be trimmed. b. Tofflemire band modified and wooden wedges.

Figure 4. Modified Tofflemire band. Arrow indicates concave area of the newly trimmed band, which will be placed toward the gingiva.

Figure 5. Proximal view of modified Tofflemire band, which was curved using finger pressure. Arrow indicates gingival side.

the mesial and distal sides to hold the matrix firmly in place and to seal the preparation against fluid contamination (Figure 6).

Restoration

The cavity surface was scrubbed with GC cavity conditioner (polyacrylic acid/aluminum chloride) with a microbrush for 10 seconds according to the manufacturer's instructions, then rinsed and lightly air dried. An A3 shade, resin-modified glass ionomer capsule (Fuji II LC, GC America, Alsip, IL, USA) was activated and mixed for 10 seconds at 4000 cpm, then the material was injected into the internal form of the cavity preparation from distal to mesial, allowing excess to cover the margins and producing an approximately 30% overcontour, and

light cured for 20 seconds with an LED light (Valo, Ultradent; Figure 7). After light curing the RMGI but before finishing, the matrix was removed with a cotton forceps (Figure 8). A finishing diamond bur (FSD4, Komet USA, Rock Hill, SC, USA) was used to obtain final contours. Excess RMGI was removed from the gingival embrasures using thin 0.078" finishing strips (Sof-Lex, 3M, St Paul, MN, USA). Medium and fine polishing discs (Sof-Lex XT, 3M) were used to obtain smooth surfaces and transitions (Figure 9).

Figure 10 shows the restorations after 2 years. The patient's treatment, which included removable partial dentures, was completed. Restoration of the left maxillary lateral incisor was intact, but some interproximal enamel decalcification was evident.

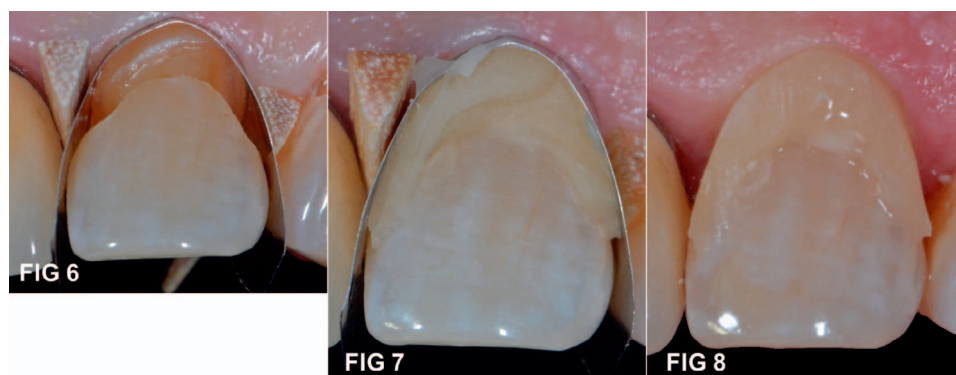


Figure 6. Modified Tofflemire band and wooden wedges placed around preparation.

Figure 7. Resin modified glass ionomer in place.

Figure 8. Band and wedges removed.

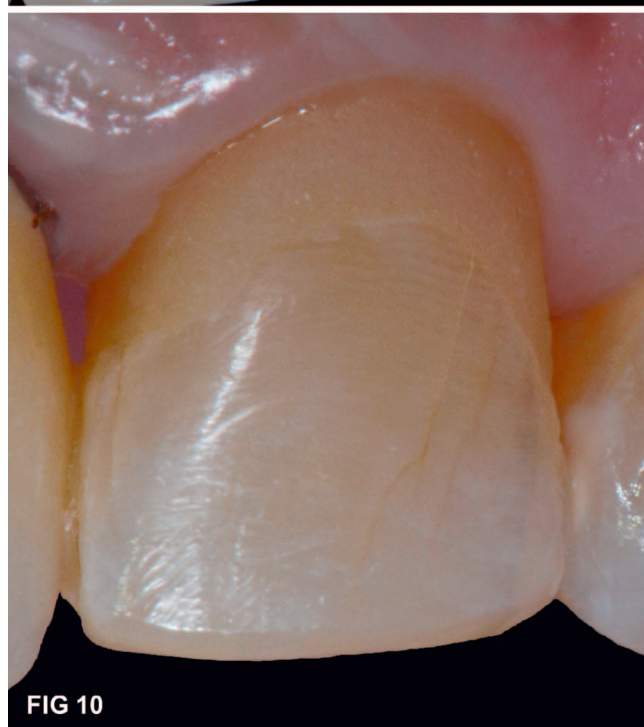
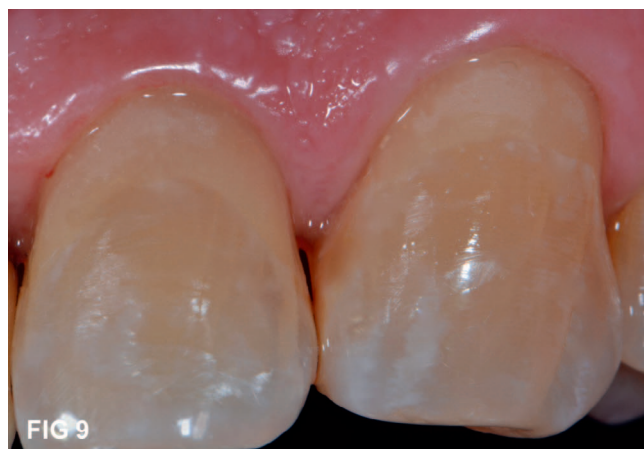
Figure 9. Final restoration.

Figure 10. Restoration 2 years later.

DISCUSSION

Restoring Class V subgingival preparations on buccal and lingual surfaces may be challenging if the lesion is extensive apically and interproximally, making it difficult to place an adequate restoration. The modified Tofflemire matrix band technique in combination with an RMGI restorative material was a good approach in this clinical case. An advantage of this technique is confinement of the restorative material in the matrix band, which produces a minimum of overhangs and proper interproximal contours; therefore, minimal finishing is required.

The advantage of using RMGI is that the materials can be applied in a bulk-fill technique without compromising marginal integrity. While these materials are not as smooth and translucent as enamel,¹² they can be overlaid with resin composite if desired.¹³

Treatment of high-risk patients such as this should include not only restorative measures but a well-designed caries-risk-management protocol and oral hygiene instructions.¹⁴ After 2 years, the patient presented with interproximal enamel decalcification lesions (Figure 10), indicating that future caries management steps should be undertaken to increase effectiveness.

CONCLUSION

The modified matrix technique, combined with an RMGI restorative material, was an effective approach for treating the subgingival root caries of this patient.

Acknowledgement

The authors gratefully acknowledge the assistance of David A. Covey, DDS, MS, in introducing them to custom cervical matrix techniques.

Regulatory Statement

This study was conducted in accordance with all the provisions of the local human subjects oversight committee guidelines and policies of the Dental College of Georgia, Augusta University.

Conflict of Interest

The authors of this manuscript certify that they have no proprietary, financial, or other personal interest of any nature or kind in any product, service, or company s presented in this article.

(Accepted 9 September 2017)

REFERENCES

1. Fedele DJ, & Sheets CG (1998) Issues in the treatment of root caries in older adults *Journal of Esthetic Dentistry* **10**(5) 243-252.
2. Mitra SB (1991) In vitro fluoride release from a light-cured glass-ionomer liner/base *Journal of Dental Research* **70**(1) 75-78.
3. Mitra SB (1991) Adhesion to dentin and physical properties of a light-cured glass-ionomer liner/base *Journal of Dental Research* **70**(1) 72-74.
4. Burgess JO (1995) Dental materials for the restoration of root surface caries *American Journal of Dentistry* **8**(6) 342-351.
5. Peumans M, De Munck J, Mine A, & Van Meerbeek B (2014) Clinical effectiveness of contemporary adhesives

- for the restoration of non-carious cervical lesions. A systematic review *Dental Materials* **30**(10) 1089-1103.
6. Hara AT, Turssi CP, Serra MC, & Nogueira MC (2002) Extent of the cariostatic effect on root dentin provided by fluoride-containing restorative materials *Operative Dentistry* **27**(5) 480-487.
 7. Haveman CW, Summitt JB, Burgess JO, & Carlson K (2003) Three restorative materials and topical fluoride gel used in xerostomic patients: A clinical comparison *Journal of the American Dental Association* **134**(2) 177-184.
 8. Davidson CL, de Gee AJ, & Feilzer A (1984) The competition between the composite-dentin bond strength and the polymerization contraction stress *Journal Dental of Research* **63**(12) 1396-1399.
 9. Brackett WW, & Rashid RG (1989) Rubber dam isolation for Class V composite resin or glass ionomer restorations *Quintessence International (Berlin : 1985)* **20**(5) 317-321.
 10. Belvedere PC, & Lambert DL (1984) A polyester matrix system for a periodontally sound, acid-etched bonded veneer *Northwest Dentistry* **63**(3) 14-16.
 11. Perez CR (2010) Alternative technique for class V resin composite restorations with minimum finishing/polishing procedures *Operative Dentistry* **35**(3) 375-379.
 12. Brackett WW, Dib A, Brackett MG, Reyes AA, & Estrada BE (2003) Two-year clinical performance of Class V resin-modified glass-ionomer and resin composite restorations *Operative Dentistry* **28**(5) 477-481.
 13. Andersson-Wenckert IE, van Dijken JW, & Kieri C (2004) Durability of extensive Class II open-sandwich restorations with a resin-modified glass ionomer cement after 6 years *American Journal of Dentistry* **17**(1) 43-50.
 14. Astroth JD (1996) Caring for the elderly adult. How to prevent, manage root surface caries *Dental Teamwork* **9**(5) 15-19.